

South Dakota State University

Open PRAIRIE: Open Public Research Access Institutional Repository and Information Exchange

Electronic Theses and Dissertations

1981

An Ultrastructural Survey of a Sarcocystis Species Found in the Wapiti of South Dakota

William Justus Soeffing

Follow this and additional works at: <https://openprairie.sdstate.edu/etd>

Recommended Citation

Soeffing, William Justus, "An Ultrastructural Survey of a Sarcocystis Species Found in the Wapiti of South Dakota" (1981). *Electronic Theses and Dissertations*. 4056.

<https://openprairie.sdstate.edu/etd/4056>

This Thesis - Open Access is brought to you for free and open access by Open PRAIRIE: Open Public Research Access Institutional Repository and Information Exchange. It has been accepted for inclusion in Electronic Theses and Dissertations by an authorized administrator of Open PRAIRIE: Open Public Research Access Institutional Repository and Information Exchange. For more information, please contact michael.biondo@sdstate.edu.

AN ULTRASTRUCTURAL SURVEY OF A SARCOCYSTIS SPECIES
FOUND IN THE WAPITI OF SOUTH DAKOTA

BY

WILLIAM JUSTUS SOEFFING

A thesis submitted
in partial fulfillment of the requirements for the
degree Master of Science
Major in Zoology
South Dakota State University
1981

AN ULTRASTRUCTURAL SURVEY OF A SARCOCYSTIS SPECIES
FOUND IN THE WAPITI OF SOUTH DAKOTA

This thesis is approved as a creditable and independent investigation by a candidate for the degree, Master of Science, and is acceptable for meeting the thesis requirements for this degree. Acceptance of this thesis does not imply that the conclusions reached by the candidate are necessarily the conclusions of the major department.

Dr. E.J. Huggins
Thesis Adviser Date

Dr. E.J. Huggins
Head, Biology Dept. Date

ACKNOWLEDGEMENTS

I extend my most sincere thanks and deepest appreciation to the following people who contributed to this study and my education.

Dr. Ernest J. Huggins, my major adviser, whose patience, assistance, and sharing of philosophies and knowledge will be eternally appreciated.

Dr. Nels Granholm, Microscopist in Animal Science, whose instruction in electron microscopy techniques proved invaluable.

Dr. Charles McMullen, Associate professor of Biology; Ms. Phyllis Johnson, Assistant in Animal Science; and Mr. Ivan Stotz, Instructor in Veterinary Science; whose friendships and sharing of technical advice, research facilities and equipment contributed to the successful completion of this study.

Mrs. Silva Trautman, Assistant instructor in Biology, whose friendship and willingness to assist in histological tissue preparations was inexhaustible.

Mr. Nicholas Grkovic, Wildlife biologist, South Dakota Department of Game, Fish, and Parks, Custer State Park; whose assistance in collecting tissue samples from hunter-harvested wapiti was very helpful.

Mr. Charles Lura and Mr. David Nomsen, whose invaluable friendships, discussions, and words of encouragement contributed to and enhanced my education.

My wife Cassandra, whose patience and encouragement was unceasing; who also deserves a special thanks for typing this manuscript.

TABLE OF CONTENTS

	Page
INTRODUCTION	1
Taxonomy	1
History	2
Life Cycle	7
Clinical Signs and Diagnosis	12
Research Objectives	13
METHODS AND MATERIALS	14
RESULTS AND DISCUSSION	18
Macroscopic Examination	18
Microscopic Examination	18
Ultrastructural Examination	20
CONCLUSIONS	25
LITERATURE CITED	29
APPENDIX	33
Abbreviations of Structural Features	34
Structural Components Terminology	35
Life Cycle Nomenclature	38
Figures (See List of Figures)	40

LIST OF FIGURES

Figure	Page
1. Radially striated cyst wall of the sarcocyst (Phase microscopy) [1,500X].....	40
2. Palisade-like protrusions of the primary cyst wall (Phase microscopy) [2,750X].....	40
3. Degenerate compartments in central regions of the sarcocyst (Phase microscopy) [2,750X].....	40
4. Primary cyst wall displaying overlapping villi and a thick underlying ground substance [14,000X].....	42
5. Palisade-like protrusions and overlying secondary cyst wall [13,800X].....	44
6. Invaginations in the unit membrane displaying pore-like structures [105,000X].....	44
7. Palisade-like protrusions displaying peripherally located microfibrils and overlying secondary cyst wall [12,600X].....	44
8. A septum separating two merozoite-filled compartments [18,200X].....	46
9. A triangular column formed by the anastomosis of septa [17,000X].....	46
10. Merozoite suspended in the granular intracompartamental matrix [41,200X].....	48
11. An oblique section through the apical complex displaying the juxtaposition of the pellicle and subpellicular microtubules [52,700X].....	50

12. An oblique section through the apical complex displaying subpellicular microtubules and a preconoidal ring [97,800X].....	50
13. Transverse section of the apical complex displaying juxtaposition of the subpellicular microtubules and the pellicle [74,100X].....	50
14. Longitudinal section through a merozoite displaying subpellicular microtubules (arrows) [50,900X].....	50
15. Oblique section through a merozoite displaying peripherally concentrated micronemes and free-ribosome embossed amylopectin granules [28,100X].....	52
16. Oblique section through a merozoite displaying a transverse section through a micropore [68,300X].....	52
17. Oblique section through a merozoite displaying peripherally concentrated micronemes and a lobular rhoptrie [34,000X].....	52
18. Transverse section through the posterior region of a merozoite displaying the nucleus surrounded by peripherally scattered micronemes [24,000X].....	52
19. The apical complex of the merozoite [48,800X].....	54
20. The apical complex of a merozoite displaying the anterior polar ring [45,000X].....	54
21. Transverse section through the apical complex displaying transverse sections of rhoptrie ductules [57,800X].....	56
22. Peripherally scattered micronemes in an oblique section of a merozoite [34,700X].....	56

23. Mitochondria and golgi bodies not contained within a unit membrane [122,000X].....	58
24. Spherical cluster of amylopectin granules embossed with free-ribosomes surrounded by concentric layers of endoplasmic reticulum [60,000X].....	58
25. Peripherally scattered micronemes and amylopectin granules in an oblique section through the posterior region of a merozoite (note the deteriorated cytoplasm in the perinuclear space) [52,000X].....	60
26. Vacuolar condensation of cytoplasm, micronemes and amylopectin granules [65,200X].....	60
27. Proposed Life Cyle of <u>Sarcocystis</u> in Wapiti and Coyote.....	62

AN ULTRASTRUCTURAL SURVEY OF A SARCOCYSTIS SPECIES
FOUND IN THE WAPITI OF SOUTH DAKOTA

Abstract

WILLIAM J. SOEFFING

A Sarcocystis species found in the wapiti (American elk) of South Dakota was macroscopically, microscopically, and ultrastructurally examined. Macroscopic and microscopic examination provided typical features of a sarcocyst, whereas ultrastructural examination revealed unique features in the primary cyst wall and a quadripartite arrangement of organelles in the merozoite.

The sarcocysts observed were shiny white elongated ellipsoids embedded in what appeared to be an intramuscular vacuole. The primary cyst wall consisted of densely packed palisade-like protrusions (villi) and a wide underlying ground substance. Distinctive features of the palisade-like villi included peripherally supportive microfibrils which did not extend into the underlying ground substance, invaginations in the unit membrane along the entire villi surfaces, and concentrations of invaginations between the basal regions.

The quadripartite arrangement of organelles in the merozoite is different from any previously described species.

The anterior, central, and posterior regions of the merozoite contained the apical complex, mitochondria/golgi bodies, and nucleus, respectively. The fourth region, consisting of peripherally concentrated micronemes and amylopectin granules, encapsulated the three former regions. The organelles of the fourth region are ordinarily incorporated into the three-region merozoite. The quadripartite arrangement of organelles may be significant to their affiliated functions.

The value of the ultrastructurally unique features found in this Sarcocystis species, as a criterion of nomenclature, is dependent upon the identification of the definitive host and completion of the parasite's life cycle. To assume that the observed sarcocysts are the only possible species infective to wapiti would be presumptuous at this time.

INTRODUCTION

Taxonomy

Taxonomic reclassification has been predominant in the history of Sarcocystis organisms since the late 1800's. Sarcocystis has been a parasitic sporozoan of uncertain systematic classification. Taxonomic classification is frequently based on life cycle and structural features. Sarcocystis may be difficult to distinguish from other closely related genera: Toxoplasma, Frenkelia, and Besnoitia (Scholtzseck, 1973). The taxonomy formalized by Levine (1973) will be the reference scheme used in this discussion. Levine (1973) classifies the Sarcocystis organism as:

Subphylum Apicomplexa Levine, 1970
Class Sporozoasida Leuckart, 1879
Subclass Coccidiasina Leuckart, 1879
Order Eucoccidiarida Leger and Duboscq, 1910
Suborder Eimeriorina Leger, 1911
Family Sarcocystidae Poche, 1913
Genus Sarcocystis Lankester, 1882

The aforementioned taxonomic classification is based on life cycle and structural features. The Sarcocystis organism must be mononucleated, heteroxenous, highly host specific, possess micropores in its cell membrane, and have a well developed apical complex. The apical complex consists of polar rings, micronemes, rhoptries, subpellicular microtubules, and a conoid. Thin septa compartmentalize the cyst, wherein elongated zoites are contained. The cysts

develop in parenteral cells of vertebrate hosts. Independent macrogamete and microgamete development, non-motile zygotes, and sporocyst encased sporozoites are also characteristic features of Sarcocystis organisms (Levine, 1973).

Attempts to assign specific binary names to the Sarcocystis species not only has led to confusion in the assignment of correct names, but also in the identification of species retaining a multitude of commonly used names (Levine, 1977). A specific binary name will not be assigned to the research organism; rather, reference to the intermediate host in which the organism was found will be made. This reference scheme should alleviate the semantics encountered by Levine (1977), who found a multitude of names for the same species. Hopefully this scheme will reduce any further confusion.

History

The first reported observation of a Sarcocystis species was made by Miescher in 1843. He had observed a species found in mouse musculature. Since that observation, considerable confusion has evolved in the naming of Sarcocystis species. The genus was named by Lankester in 1882, with regard to Sarcocystis miescheri. Conflict evolved when the same species of this parasite, found in pork musculature, was discovered to bear previous nomenclature. The generic name assigned by Kuehn in 1865, Synchytrium

miescherianum, had been previously used, and therefore was unavailable. Lankester had assigned the proper nomenclature to this species. It has become known as Sarcocystis miescheriana (Kuehn 1865) Labbe 1899, only after Labbe substituted Sarcocystis for the previous genus name. Many of the species found after this time have also been assigned erroneous nomenclature (Levine, 1977).

In 1943, Scott recognized the parasite as an amoeba-like parasite of striated muscle. He believed that no intermediate host was necessary in the transmission of the parasitic infection. The infectious stage was transmitted via the fecal contamination of food resources. Merozoites would escape the muscle cyst, be transported by the vascular system to the digestive system, and escape into the excrement. Scott stated that natural transmission of the infection via ingestion of merozoites by herbivores was impossible. Scott also concluded the absence of sarcocysts in the carnivore's musculature disqualified the natural transmission of sarcocystosis via the ingestion of the herbivore's musculature (Keem, 1974).

By 1945, Spindler and Zimmerman had reported Sarcocystis species to be the fungus Aspergillus sp.. They found mycelia with vertical hyphae bearing spores in sterile dextrose solution cultures (Spindler and Zimmerman, 1945). Spindler et al. (1946) reported dogs, cats, rats, mice, and

chickens transmitted the infection to swine via their excrement. Auto-infection was also possible in swine due to coprophagic behavior. Photographs published by Spindler (1947) demonstrated that the sarcocysts were not individuals, but fungal mycetoma. Purohit and D'Souza (1973) reported that the merozoites ("spores") contained in the sarcocysts were PAS-positive, and could be regarded as fungi.

Ludvik (1958, 1960) and Simpson (1966) defined Sarcocystis as a protozoan, relative to its ultrastructural organelles and unicellular nature. The ultrastructure of Frenkelia sp. zoites resembled those of Toxoplasma sp., Besnoitia sp. and Sarcocystis sp. (Scholtyseck, et al., 1970).

The cell culture of Sarcocystis species merozoites was successfully completed by Fayer (1970). Fayer (1972) reported the observation of the gametogonous stage of the Sarcocystis life cycle in cell culture. Fayer concluded that the merozoites found in the sarcocysts gave rise to the sexual stages of the life cycle and that a cyst-like structure found after gametogony was an oocyst.

Heydorn and Rommel (1972) and Mahrt (1973) reported finding sporulated sporocysts in the excrement of dogs, after having fed them Sarcocystis-infected beef. Mahrt concluded that the sporocysts were of intestinal origin. The gametogonous stage with the formation of oocyst-like

structures and the expulsion of sporulated sporocysts gave substance to the proposed intestinal stage of the life cycle found in the carnivore.

Fayer and Johnson (1973, 1974) completed the life cycle by reinfesting the herbivorous host with sporocysts obtained from the carnivorous host. Fayer and Leek (1973) described the excystation of sporozoites from the sporocyst in the herbivorous host's intestines.

The life cycle was shown to involve two vertebrate hosts. The carnivorous host ingests infected musculature from the herbivorous host. Merozoites in the musculature excyst and undergo gametogony and sporogony in the carnivore's intestines, as previously described by Fayer (1972), Mahrt (1973), Fayer and Johnson (1973, 1974), and Fayer and Leek (1973). Sporocysts in the carnivore's excrement contaminate food resources. The sporocyst-contaminated food resources are consumed by the herbivorous host. Sporozoites 'excyst' from the ingested sporocysts, penetrate the intestinal wall, distribute themselves through the host via the vascular system and encyst (Fayer and Leek, 1973). The encysted cells undergo multiple asexual divisions giving rise to merozoites and subsequently a mature cyst. As early as 1943, Scott described schizogony in the herbivorous host with astounding accuracy. Only in attempting to explain the transmission of sarcocystosis did he formulate erroneous

conclusions. Not until the early 1970's have the gametogonous and sporogonous stages of the life cycle been described. The conclusions drawn from the aforementioned studies were verified almost immediately after their disclosure (Fayer and Johnson 1973, 1974; Wallace, 1973).

Since the mid-1970's research emphasis has been in three major directions: hematological and serological studies of Sarcocystis antibodies (Mahrt and Fayer, 1975; Lunde and Fayer, 1977; Thomas and Dissanaiké, 1978); life cycle and morphological descriptions of Sarcocystis in small game and free-ranging herbivores (Keem, 1974; Hudkins et al., 1976; Fayer and Kradel, 1977; Hudkins and Kistner, 1977; Pond and Speer, 1979; Dubey, 1980a, 1980b); and comparative ultrastructural studies (Scholtyseck, 1973; Scholtyseck et al., 1974; Mehlhorn et al., 1976; Mehlhorn and Heydorn, 1978).

Historically, the proper taxonomical relationships, morphology, life cycles, and ultrastructure of Sarcocystis species are recent knowledge. Research in the 1960's provided data which portrayed Sarcocystis as a protozoan. In the 1970's, the life cycle of the parasite was completed. Finally, the 1980's will provide immunological and extensive ultrastructural data. To date, most research has been academic, but the reservoir of knowledge which has been accumulated should prove applicable in the treatment of sarcocystosis.

Life Cycle

Sarcocystis demonstrates a life cycle similar to that of other coccidial parasites, except for a unique alternation of merogonous and gametogonous/sporogonous stages between herbivores and carnivores, respectively (Hudkins and Kistner, 1977). The obligatory two host life cycle typically utilizes the herbivore as the intermediate host and the carnivore as the definitive host (Dubey, 1976).

The life cycle alternates between asexual and sexual reproductive stages as the intermediate and definitive hosts alternate, respectively. Merogony or the asexual stage of the life cycle is prevalent in the endothelial tissues of the vascular system. The sexual reproductive stage, gametogony, occurs in the lamina propria of the intestinal mucosa. Sporogony, a stage which may be more of developmental than reproductive value, follows the other two reproductive stages. Merogony occurs in the herbivorous intermediate host, while gametogony and sporogony occur in the carnivorous definitive host (Mehlhorn and Heydorn, 1978).

The intermediate host contracts sarcocystosis by ingesting sporocysts shed by the definitive host. Sporozoites are released from the sporocysts in the intestine of the intermediate host (Dubey, 1976). The development of Sarcocystis in the intermediate host appears in two stages, extraintestinal merogony and cyst formation. The first

appearance of merozoites in the intermediate host's vascular system varies. The length of the post-infection period from initial infection to merozoite emergence in the vascular tissues may indicate a difference between the Sarcocystis species parasitizing the same host (Mehlhorn and Heydorn, 1978). The period length may vary from 4-17 days in the mouse (Ruiz and Frenkel, 1976), 4-9 days in rats and pigs (Fayer and Johnson, 1973; Zaman and Colley, 1975), or 15 days in sheep and cattle (Mehlhorn and Heydorn, 1978). Merogony occurs in the endothelial cells of the vascular tissue of many organs after being transported from the intestines by the vascular system. A widespread infection is thereby facilitated by the parasite's invasion of the vascular system (Dubey, 1976). Endodyogeny may occur before the parasite leaves the endothelial tissues (Mehlhorn et al., 1976, 1977). After approximately 30 days post-infection, the parasite leaves the endothelial cells of the vascular system and invades the muscle tissue in the surrounding area (Mehlhorn et al., 1976, 1977).

Intramuscular encystment follows the parasite's developmental migration (Dubey, 1976). Cyst development occurs within a single muscle cell and may practically fill an entire muscle cell in the case of "old cysts" (Mehlhorn and Heydorn, 1978). An invading merozoite will form a parasitophorous vacuole, which will have a single unit

membrane. An underlying osmiophilic layer is deposited, forming the primary cyst wall (20-100 μm) (Mehlhorn et al., 1976, 1977).

Characteristic to the primary cyst wall are vesicular depressions (approximately 40 nm in diameter) which are associated with absorption. The depressions may be restricted to spaces between protrusions (palisade-like villi) or may cover the entire surface of the cyst. Those species of Sarcocystis which have the palisade-like protrusions in mature cysts may appear to have a radially striated "thick wall" (10 μm). Other species may have "thin walls" (1 μm) (Mehlhorn and Heydorn, 1978).

An amorphous ground substance develops beneath the primary cyst wall. This ground substance lines and forms the compartments of the cyst. The septa forming the compartments may vary in thickness and give the cyst structural strength. The peripheral zone of ground substance is thicker in species which have no or short cyst wall protrusions (Mehlhorn and Heydorn, 1978).

A secondary cyst wall may develop in Sarcocystis species which approach very large sizes, i.e., Sarcocystis tenella (1-5 cm in length). This secondary cyst wall is composed of fibrillar material (connective tissue) and may approach 4 μm in thickness (Mehlhorn and Heydorn, 1978).

The ultrastructural features of the primary cyst wall, its variations, and the presence of other ultrastructural components are characteristic of each species. Morphology cannot be used for absolute species identification or differentiation. The parasite determines the structure of the primary cyst wall and its underlying cellular components (Mehlhorn and Heydorn, 1978). The developmental independence demonstrated by the parasite accounts for cyst wall variations found within the same host, between individuals of the same host species, and among individuals of different host species.

The definitive host acquires the infection by ingesting the encysted form of the parasite found in the musculature of the intermediate host. Merozoites are released from the intramuscular cyst by proteolytic enzymes after ingestion of the infected muscle tissue by the definitive host. The merozoites penetrate the lamina propria of the mucosa in the small intestines and form gamonts (macrogametes and microgametes). Fertilization of the macrogamete by the microgamete gives rise to unsporulated oocysts (Dubey, 1976). Zygotes and oocysts may be found in the latter third of the duodenum, and all of the jejunum and ileum (Speer et al., 1980). Oocysts sporulate and form two sporocysts (sporogony). Within the sporocyst develop several sporozoites. The thin-walled oocysts (0.1 μm) generally

rupture, releasing the sporocysts into the lamina propria and ultimately into the excrement. This rupturing of the oocysts accounts for the infrequent appearance of sporulated oocysts in the feces (Dubey, 1976).

The prepatent and patent periods of the infection differ greatly among the varying Sarcocystis species and their hosts (Mehlhorn and Heydorn, 1978). Comparisons between studies disclose the variable and inconsistent methods of quantifying infective units in a given intermediate host tissue sample. The definitive host species and individual differences within the species may also alter the duration of prepatent and patent periods of the infection. As a result of these variables, it is difficult to ascertain any relationships which may exist between the parasite species and its host species (Margolin and Jolley, 1979). Some regularity exists in the duration of sarcocystosis prepatent periods in the carnivorous host, when inoculated with infected tissues from the free-ranging herbivores. Coyotes (Canis latrans) fed infected mule deer (Odocoileus hemionus) muscle tissue started shedding sporocysts and oocysts 9-13 days post-inoculation (Hudkins and Kistner, 1977; Speer et al., 1980). Domestic dogs (Canis familiaris) fed infected wapiti (Cervus elaphus [=canadensis]) muscle tissue started shedding sporocysts and oocysts 14 days post-inoculation (Margolin and Jolley, 1979).

Coyotes fed infected wapiti muscle tissue started shedding sporocysts 10 days post-inoculation. Sporocysts were shed from both the coyote and domestic dog 12 days post-inoculation of infected moose (Alces alces) tissue. Eleven days post-inoculation of coyotes with infected bison (Bison bison) muscle tissue, sporocysts were shed (Dubey, 1980b).

Clinical Signs and Diagnosis

Clinical signs of sarcocystosis are: anorexia, pyrexia, lymphadenopathy, anemia, ataxia, excessive salivation, petechiae of serosal membranes, abortions, and loss of hair at the tip of the tail. The pathogenic characteristics of the infection in the intermediate host are observable during the parasitism of the endothelial cells by meronts. The cyst stage of the infection is non-pathogenic. Sarcocystis is non-pathogenic to the definitive host (Dubey, 1976; Giles et al., 1980).

Diagnosis may be facilitated by using the clinical signs, but other tests are available. Serum glutamicoxalacetic transaminase (SGOT), lactic dehydrogenase (LDH), and creatinine phosphokinase (CPK) activities, and hematologic data may aid in the proper diagnosis (Mahrt and Fayer, 1975; Giles et al., 1980). An indirect hemagglutination (IHA) test titer is also available, whereby the infection concentration may be estimated (Lunde and Fayer, 1977; Giles et al., 1980).

The key factor in the spreading of sarcocystosis is the shedding of sporocysts in the excrement of carnivores. The large number of sporocysts in coyote intestines and excrement suggests that the coyote has an important role in the spreading of sarcocystosis to livestock and big game of the western United States (Dubey, 1980a). Control efforts would need to interrupt the life cycle. The carnivorous definitive host has no immunity to reinfection and may cause further dispersal of the infective sporocysts (Fayer, 1974). Anticoccidial drugs may reduce infections in the intermediate host (Fayer and Johnson, 1975).

Research Objectives

This study was undertaken to survey the ultrastructural features of a Sarcocystis species found in the wapiti of South Dakota. The objectives of the study were to:

1. Demonstrate, pictorially, the ultrastructure of the Sarcocystis species found in the wapiti of South Dakota.
2. Determine any ultrastructurally unique features of the Sarcocystis species found in the wapiti.
3. Compare and contrast the ultrastructural features of the species found in the wapiti with those of other Sarcocystis species, denoting those features which might contribute to its taxonomic classification.

METHODS AND MATERIALS

Tongue muscle tissue samples were collected from annual hunter-harvested wapti (Cervus elaphus) (Jones et al., 1975) in Custer State Park, Hermosa, South Dakota. These samples were macroscopically examined for Sarcocystis. Cysts were dissected out and placed in one-dram glass shell vials containing 2 ml of Sorensen's buffered 2% gluteraldehyde adjusted to pH 7.4 (Bils, 1974). The tissue was prefixed in this solution for 8 hours and 25 minutes at 21°C before any further tissue processing techniques were performed.

Extended processing times and special handling care were needed in preparing the 'thick-walled' sarcocysts. Sorensen's buffer solution adjusted to pH 7.4 (Bils, 1974), was used in two consecutive five minute washes after prefixation. A final 30 minute wash was used to ensure the complete removal of the prefixative. Sorensen's buffered osmium tetroxide adjusted to pH 7.4, (Bils, 1974) was used as the postfixative for 10 hours and 45 minutes at 24°C. The postfixative was removed with two consecutive five minute washes followed by a 30 minute wash using Sorensen's buffer solution. The tissue was dehydrated using a gradual gradient change in the concentration of ethyl alcohol solutions. Each cold (4°C) concentration of 10%, 30%, 50%, 70%, 90%, and 100% ethyl alcohol was used for ten minutes and then replaced with

the next higher concentration. Two final dehydration steps were performed with cold 100% ethyl alcohol. Each was allowed to rise to room temperature (21°C) before proceeding (approximately 30 minutes for each of the two steps). Propylene oxide was used for one 5 minute and one 20 minute pre-infiltration embedment solvent step. A 3:1 mixture of propylene oxide and Bo-Jax/Spurr embedment (McMullen et al., 1977) was used for infiltration followed by a 2:1 mixture and a 1:1 mixture. The final 1:1 mixture was left in the tissue processing vial for 13 hours with the cap removed; this allowed the remaining propylene oxide to evaporate and leave pure embedment in the tissues.

Re-embedment required the exchange of the old embedment with fresh embedment. Tissue samples were transferred from the old embedment into a latex rubber flat mold. Each truncated pyramid recess in the mold had been prepared by depositing, in the tip, one drop of fresh embedment. This facilitates the orientation of the tissue sample. The tissue was orientated in the truncated recess so that cross sections of the cysts could be obtained. After the tissue was in place, the recesses were filled with fresh embedment, labeled, and placed in a polymerization oven. The tissue blocks were polymerized for 24 hours at 60°C. After cooling, the blocks were removed from the flat mold and allowed to set for several days.

The tissue blocks were adhered to cylindrical epoxy blanks with a rapidly polymerizing adhesive. These tissue blocks were allowed to polymerize at room temperature (21°C) for 12 hours or more. This was done to ensure the complete fusion of the pyramidal tissue block to the epoxy cylinder. Had this not been done, the tissue block may have been evulsed from the epoxy cylinder during trimming or sectioning.

Tissue block faces were trimmed with a single edge razor blade into approximately a .25 mm² trapezoid. Thin sections were cut with glass knives on a DuPont-Sorvall MT2-B ultramicrotome, placed on acid-cleaned 300 mesh copper grids, and stained with 5% uranyl acetate and lead citrate (Bils, 1974). The grids were stained in disposable petri dishes to reduce contamination and chemical precipitation. The grids were stained in the uranyl acetate for one hour, rinsed thoroughly in distilled water, stained in lead citrate for one minute, and rinsed thoroughly in fresh distilled water. The grids were dried and stored in grid storage boxes until examination. Ultrastructural observations and photographs were made on a Hitachi HU-12 transmission electron microscope. Thick sections were also cut with glass knives on a DuPont-Sorvall MT2-B ultramicrotome at a thickness of 3µm. The thick sections were taken from the same block of which thin sections were made. The sections were placed on a clean glass slide, submerged in immersion oil, and covered with a

glass cover slip. Microscopic observation and photographs were made on a Wild M20 research microscope with an attached Micro-Photoautomat MKa-4 automatic exposure photographic system. Phase microscopy techniques were used to enhance the detail of the unstained thick sections.

RESULTS AND DISCUSSION

Macroscopic Examination

The sarcocysts observed were shiny white elongated ellipsoids (1.5 x 0.4 mm) embedded in and longitudinally striated with the muscle fibers of the tongue musculature. The immediately surrounding muscle tissue was teased away from the sarcocysts with minimal resistance, as though the cysts occupied intramuscular vacuoles.

Microscopic Examination

Phase microscopy examination revealed a 'radially striated' cyst wall [Fig. 1] similar to those found in Sarcocystis species of cattle, sheep, and elk (Mehlhorn et al., 1976; Mehlhorn and Heydorn, 1978; Keem, 1974). Closer examination revealed densely packed palisade-like protrusions (villi) overlaid with connective tissue (perhaps a secondary cyst wall), and underlaid with an amorphous osmiophilic ground substance [Fig. 2]. Mehlhorn et al. (1976) provided a detailed description of the development and morphology of the palisade-like protrusions from the initial deposition of the unit membrane to the completion of the primary cyst wall complex.

The underlying amorphous osmiophilic ground substance was extremely thick (0.7 μm), relative to the length of the villi (3.5 μm). Contemporary observations have depicted an

inverse relationship between the thickness of the ground substance and the length of the villi. Sarcocysts with short villi had an extensive peripheral ground substance, whereas those with long villi had a limited ground substance (Mehlhorn et al., 1976; Mehlhorn and Heydorn, 1978). The ground substance traversed the interior of the cyst to form septa. The septa were of considerable thickness (0.7 μm) as was the peripheral ground substance constituting the primary cyst wall. The septa may provide structural stability to the cyst through compartmentalization (Mehlhorn and Heydorn, 1978).

The peripheral compartments contained well defined merozoites separated by chamber-like hollows of the ground substance described by Mehlhorn and Heydorn (1978). The central regions of the sarcocyst appeared degenerate [Fig. 3]. The septa composing the compartments were fragmented and the merozoites appeared lysed and condensed. Mehlhorn and Senaud (1975) described degenerate cysts in Sarcocystis tenella of sheep. A lytic bacterium found within their cysts may have led to the deterioration of the merozoites' pellicles. Some of the inner compartments of their mature cysts were completely degenerated and empty. Some of the centrally located compartments of this study's sarcocysts appeared nearly empty, also. Sarcocystin, a zymogen form of endotoxin, is activated upon release from degenerating zoites (Keem, 1974). The toxin acts on the central nervous system, heart,

adrenal glands, liver, and intestinal wall of the host (Levine, 1961).

Ultrastructural Examination

An ultrastructural survey of the primary cyst wall verified the existence of palisade-like villi underlaid by an amorphous osmiophilic layer [Fig. 4]. The secondary cyst wall was not as prevalent as it had appeared when examined with phase microscopy [Fig. 5 and Fig. 7]. The ground substance formed a wide zone from which wide septa traversed the interior of the cyst.

An electron dense unit membrane, averaging a width of 45 nm, constituted the peripheral surface of the palisade-like villi. The villi averaged a length of 3.5 μm with a diameter of 1.2 μm . The entire surface of the villi had invaginations similar to those described by Mehlhorn et al. (1976), which suggested an absorption facilitating function. Those areas between the villi, close to the base of the protrusions, demonstrated an increased number of invaginations and structures closely resembling pores [Fig. 6]. The pore-like structures traversed the unit membrane with the apex of their hyperbolic shape contacting the underlying microfibrils and fibrillar elements. The diameters of the pores averaged 30 nm. The villi were composed of fibrillar elements centrally located in the protrusions surrounded by

microfibrils [Fig. 7]. The microfibrils did not extend into the ground substance, but a dense deposition of fibrillar elements stippled the zone of contact between the villi and ground substance.

The secondary cyst wall observed with phase microscopy, ultrastructurally appeared to be the deposition of cellular component fragments. Membrane fragments and degenerate mitochondria of the muscle host cell constituted the majority of the deposited components. The width of this 'layer' approached 1.5 μm .

Fibrillar elements and granules composed the ground substance underlying the villi protrusions of the cyst wall. The ground substance showed dramatic ranges in width, at times approaching 3.6 μm . Due to this inconsistent width of the ground substance, the total width of the primary cyst wall complex occasionally exceeded 7.0 μm . Vacuolar structures were frequently observed in these areas of exceptional width.

Extending internally from the peripheral ground substance were very wide septa approaching widths of 1.2 μm and averaging 1.0 μm [Fig. 8]. No microfibrils were observed in the septa; they appeared to consist of fibrillar elements and granules similar to that of the peripheral ground substance. The anastomosis of septa created triangular columns [Fig. 9] which may be structural supports for massive sarcocysts, as was suggested by Mehlhorn and Heydorn (1978).

Merozoites were suspended in an electron dense granular matrix within the compartments of the sarcocysts [Fig. 10]. Hundreds of merozoites could be observed in a single plane section through a compartment; there seemed to be no systematic significance to their arrangement. The interface between the ground substance of the peripheral region and the septa was well defined, no gradation between the different matrices being observed.

Individual merozoites displayed a trilaminar pellicle supported by subpellicular microtubules. The inner, middle, and outer membranes of the pellicle were discernible. Twenty-two longitudinal subpellicular microtubules [Figs. 11-14] appeared to be connected by transverse microtubules. This lattice framework was observed by Simpson and Forrester (1973), who suggested the microtubules may give rigid support to the merozoites.

Simpson (1966) described three 'well-defined regions' of the merozoite. The anterior third contained micronemes arranged in regular rows. The midzonal region was 'moderately distinct' with electron-dense granular bodies and mitochondria. The surrounding cytoplasm had a dense mass of free-ribosomes. The posterior third contained the nucleus and some elongated mitochondria. In contrast, the merozoites observed in the South Dakota study did not appear to have the same differentiation [Figs. 15-18].

The electron dense conoid of the apical complex occupied an anterior position in the merozoite [Fig. 19]. Polar rings, observed only in cross section, transversely circumscribed the conoid and underlaid the subpellicular microtubules of the pellicle [Fig. 20]. The ductules of the rhoptries passed through the conoid to the most anterior positions of the merozoite [Fig. 21]. Unlike the typical pear-shaped saccular rhoptries, the observed rhoptries were deeply invaginated to give them a lobular appearance. The aforementioned organelles of the apical complex were properly positioned relative to their functional affiliations (Scholtyseck, 1973; Mehlhorn and Heydorn, 1978). The micronemes were numerous and distributed contrary to the observations made by Simpson (1966). Micronemes were scattered anteriorly and posteriorly throughout the cytoplasm, but retained a peripheral posture [Fig. 22]. Dense masses of micronemes tended not to occupy the central regions of the merozoite; those areas were occupied by mitochondria and golgi bodies [Fig. 23].

Also scattered throughout the cytoplasm of the merozoites were amylopectin granules [Figs. 24-25]. Spherical clusters of amylopectin granules, embossed with free-ribosomes, were frequently observed [Fig. 24]. Immediately surrounding the amylopectin granule clusters were concentric layers of endoplasmic reticulum. Occasionally, a

vacuolar condensation of cytoplasm, micronemes, and amylopectin granules would be observed [Fig. 26]. These vacuole-like structures were always densely embossed with free-ribosomes.

The merozoites observed in this study displayed a homogenous cytoplasm with peripherally dispersed micronemes and amylopectin granules. The central regions of the cell contained the mitochondria and golgi bodies. The apical complex with its irregularly shaped rhoptries held the typical anterior positions and the nucleus retained its posterior position. The organization of this Sarcocystis species would best be described as quadripartite. Similar to the three region arrangement observed by Simpson (1966), this species possessed yet a fourth region which encapsulated the three former regions. The fourth region is best illustrated in cross section, displaying the peripherally concentrated micronemes and amylopectin granules.

CONCLUSIONS

The most distinguishable feature of the investigated Sarcocystis species is the primary cyst wall. A primary cyst wall like the one in this study has not been previously described. Distinctive features of the palisade-like villi included: peripherally supportive microfibrils which did not extend into the underlying ground substance, invaginations in the unit membrane along the entire villi surfaces, and concentrations of invaginations between the basal regions. The long villi and wide underlying ground substance of the primary cyst wall were contrary to the typical inverse relationships of the villi length to ground substance width. The occurrence of vacuolar structures in the ground substance is perhaps a response to a formidably wide primary cyst wall. The vacuoles could facilitate nutrient acquisition via pinocytosis and phagocytosis.

The maturity of the sarcocysts is illustrated by the absence of metrocytes and the degeneration of merozoites. No metrocytes were observed, which strongly suggests that the asexual reproductive activities of the schizogonous stage had been completed. The degeneration and condensation of the merozoites (which occupy the central compartments of the sarcocyst) reflected the observations of degenerate cysts made by Mehlhorn and Senaud (1975) and Munday et al. (1975).

The release of sarcocystin from the degenerating merozoites may have had a degenerative influence on adjacent merozoites and compartments. Chamber-like hollows around merozoites were not observed in the centrally located compartments of the sarcocysts. Instead, intracompartamental ground matrix appeared dispersed. Organelles were frequently observed suspended in the intracompartamental ground matrix, disassociated from any cellular membranes. It is obvious that portions of the sarcocyst had degenerated; what influence this condition had on the ultrastructural morphology of the sarcocyst is speculative.

The quadripartite arrangement of organelles in the merozoites is different from any previously described species. The fourth organelles of the region, consisting of micronemes and amylopectin granules, are ordinarily incorporated into the typical three-region merozoite. Perhaps the peculiar arrangement of the quadripartite merozoite reflects the affiliated functions of the organelles in its life cycle. Investigation into the developmental stages of this species' life cycle would be necessary to generate this information. The use of domesticated wapiti could best facilitate the timing and inoculation of the infection. Controlled completion of the life cycle in the definitive host would also be required.

Hughins (personal communication, 1979) has observed sarcocysts of two general size groups in histological sections of South Dakota wapiti musculature. The occurrence of two distinct size groups may indicate the presence of mature cysts of separate species, rather than a single maturing species. A maturing sarcocyst would demonstrate developmental cyst wall variations, gradation in cyst size, and asexual reproductive activities. It is possible the larger of the two size groups is represented in this study. Keem (1974) may have observed a similar, if not the identical Sarcocystis species in the Wyoming wapiti. Comparisons between the microscopic morphologies of the 'radially striated' cyst wall of the Wyoming species and the palisade-like villi of the South Dakota species suggest their similarity.

Speer (personal communication, 1981) observed a Sarcocystis species in wapiti from western Montana which displayed a dramatically different cyst wall. Ultrastructural examination of that cyst wall revealed superficially folded protrusions constituting a portion of the cyst wall. It is therefore obvious that more than one form of sarcocyst parasitizes the wapiti, one form with short protrusions and the other form with villi-like protrusions. Speer reported the size of the Montana sarcocysts as macroscopic, but considerably smaller than those investigated

in this study. Perhaps the smaller species observed by Huggins is represented in Speer's study. If the differing ultrastructural morphologies of the cyst walls of the two sarcocysts could be used as the sole criterion of speciation, then the occurrence of two Sarcocystis species would be clearly demonstrated. This does not imply that two Sarcocystis species from wapiti exist, nor does it disqualify that possibility.

The Sarcocystis species found in the wapiti of South Dakota has some ultrastructurally unique features, but to assume that the observed sarcocysts are the only possible infective species of the wapiti would be presumptuous. The value of ultrastructural morphology as a criterion of species identification and differentiation is related to the origin of the infection, the definitive host. The maturing parasite determines the cyst wall configuration, not the intermediate host. This is illustrated by Sarcocystis species possessing differing cyst walls in the same host (Mehlhorn and Heydorn, 1978). Identification of the definitive host and completion of the parasite's life cycle will be necessary to confidently determine the status of Sarcocystis species in the wapiti.

LITERATURE CITED

- Bils, R. F. 1974. Electron microscopy-laboratory manual and handbook. Western Publishing Co., Los Angeles, California, 278p.
- Dubey, J. P. 1976. A review of Sarcocystis of domestic animals and other coccidia of cats and dogs. J. Am. Vet. Med. Assoc. 169:1060-1078.
- _____. 1980a. Coyotes as a final host for Sarcocystis species of goats, sheep, cattle, elk, bison, and moose in Montana. Am. J. Vet. Res. 41:1227-1229.
- _____. 1980b. Sarcocystis species in moose (Alces alces), bison (Bison bison), and pronghorn (Antilocapra americana) in Montana. Am. J. Vet. Res. 41:2063-2065.
- Fayer, R. 1970. Sarcocystis: Development in cultured avian and mammalian cells. Science 168:1104-1105.
- _____. 1972. Gametogony of Sarcocystis sp. in cell culture. Science 175:65-67.
- _____. 1974. Development of Sarcocystis fusiformis in the small intestine of dogs. J. Parasitol. 60:660-665.
- _____, and A.J. Johnson. 1973. Development of Sarcocystis fusiformis in calves infected with sporocysts from dogs. J. Parasitol. 59:1135-1137.
- _____, and _____. 1974. Sarcocystis fusiformis: Development of cysts in calves infected with sporocysts from dogs. Proc. Helminthol. Soc. Wash. 41:105-108.
- _____, and _____. 1975. Effect of Amprolium on acute sarcocystosis in experimentally infected calves. J. Parasitol. 61:932-936.
- _____, and D. Kradel. 1977. Sarcocystis leporum in cottontail rabbits and its transmission to carnivores. J. Wildl. Dis. 13:170-173.
- _____, and R.G. Leek. 1973. Excystation of Sarcocystis fusiformis sporocysts from dogs. Proc. Helminthol. Soc. Wash. 40:294-296.

- Giles, R.C., Jr., R. Tramontin, W.L. Kadel, K. Whitaker, D. Miksch, D.W. Bryant, and R. Fayer. 1980. Sarcocystosis in cattle in Kentucky. *J. Am. Vet. Med. Assoc.* 176:543-548.
- Hudkins, G. and T.P. Kistner. 1977. Sarcocystis hemionilatrantis (Sp.n.): Life cycle in mule deer and coyotes. *J. Wildl. Dis.* 13:80-84.
- Hudkins-Vivion, G., T.P. Kistner, and R. Fayer. 1976. Possible species differences between Sarcocystis from mule deer and cattle. *J. Wildl. Dis.* 12:86-87.
- Jones, J.K., Jr., D.C. Carter, and H.H. Genoways. 1975. Revised checklist of North American mammals north of Mexico. *Occas. Papers. Mus., Texas Tech. Univ.* 28:1-14.
- Keem, M.D. 1974. Some aspects of sarcosporidiosis in Wyoming elk (Cervus canadensis). M.S. Thesis. Dept. Zool. and Physiol. University of Wyoming, Laramie, Wyoming.
- Levine, N.D. 1961. Protozoan parasites of domestic animals and of man. Burgess Publishing Co., Minneapolis, Minnesota, 412p.
- _____. 1973. Introduction, history, and taxonomy. In D. Hammond with P.L. Long (eds.), *The coccidia*. University Park Press, Baltimore, Maryland, pp. 1-22.
- _____. 1977. Nomenclature of Sarcocystis in the ox and sheep and of fecal coccidia of the dog and cat. *J. Parasitol.* 63:36-51.
- Ludvik, J. 1958. Elektronoptische Befunde zur Morphologie der Sarcosporidien (Sarcocystis tenella Railliet, 1886). *Zentralbl. Bakteriol. Parasitenkd. Abt. I:Orig.* 172:330-350.
- _____. 1960. The electron microscopy of Sarcocystis miescheriana. (Kuehn 1865). *J. Protozool.* 7:128-135.
- Lunde, M.N., and R. Fayer. 1977. Serologic tests for antibody to Sarcocystis in cattle. *J. Parasitol.* 63:222-225.
- Mahrt, J.L. 1973. Sarcocystis in dogs and its probable transmission from cattle. *J. Parasitol.* 59:588-589.
- _____, and R. Fayer. 1975. Hematologic and serologic changes in calves experimentally infected with Sarcocystis fusiformis. *J. Parasitol.* 61:967-969.

- Margolin, J.H., and W.R. Jolley. 1979. Experimental infection of dogs with Sarcocystis from wapiti. J. Wildl. Dis. 15: 259-262.
- McMullen, C.R., W.S. Gardner, and G.A. Myers. 1977. Ultrastructure of cell-wall thickenings and paramural bodies induced by barley stripe mosaic virus. Phytopathology 67:462-467.
- Mehlhorn, H., and A.O. Heydorn. 1978. The Sarcosporidia (Protozoa, Sporozoa): Life cycle and fine structure. In W.H.R. Lumsden, R. Muller, and J.R. Baker (eds.), Advances in parasitology. Academic Press, New York, New York 16:43-92.
- _____, and J. Senaud. 1975. Action lytique des bacteries presentes dans les kystes de Sarcocystis tenella. Arch. Microbiol. 104-:241-244.
- _____, W.J. Hartley, and A.O. Heydorn. 1976. A comparative ultrastructural study of the cyst wall of 13 Sarcocystis species. Protistologica 12:451-467.
- _____, A.O. Heydorn, and K. Janitschke. 1977. Light and electron microscopical study of Sarcocystis from muscles of the rhesus monkey (Macaca mulatta), baboon (Papio cynocephalus) and tamarin (Saguinus (=Oedopomidae) oedipus). Z. Parasitenkd. 51:165-178.
- Munday, B.L., I.K. Barker, and M.D. Rickard. 1975. The developmental cycle of a species of Sarcocystis occurring in dogs and sheep, with observations on pathogenicity in the intermediate host. Z. Parasitenkd. 46:111-123.
- Pond, D.B., and C.A. Speer. 1979. Sarcocystis in free-ranging herbivores on the National Bison Range. J. Wildl. Dis. 15:51-53.
- Purohit, S., and B. D'Souza. 1973. An investigation into the mode of transmission of sarcosporidiosis. Brit. Vet. J. 129:230-235.
- Ruiz, A. and J.K. Frenkel. 1976. Recognition of cyclic transmission of Sarcocystis muris by cats. J. Infect. Dis. 133:409-418.
- Scholtzseck, E. 1973. Ultrastructure. In D. Hammond with P.L. Long (eds.), The coccidia. University Park Press, Baltimore, Maryland, pp. 81-144.

- _____, H. Mehlhorn, and K. Friedhoff. 1970. The fine structure of the conoid of Sporozoa and related organisms. *Z. Parasitenkd.* 34:68-94.
- _____, _____, and B.E.G. Mueller. 1974. Feinstruktur der Cyste und Cystenwand von Sarcocystis tenella, Besnoitia jellisoni, Frenkelia sp. und Toxoplasma gondii. *J. Protozool.* 21:284-294.
- Simpson, C.F. 1966. Electron microscopy of Sarcocystis fusiformis. *J. Parasitol.* 52:607-613.
- _____, and D. Forrester. 1973. Electron microscopy of Sarcocystis sp.: Cyst wall, micropore, rhoptries, and an unidentified body. *Int. J. Parasitol.* 3:467-470.
- Speer, C.A., D.B. Pond, and J.V. Ernst. 1980. Development of Sarcocystis hemionilatrantis Hudkins and Kistner, 1977 in the small intestine of coyotes. *Proc. Helminthol. Soc. Wash.* 47:106-113.
- Spindler, L. 1947. A note on the fungoid nature of certain internal structures of Miescher's sacs (Sarcocystis) from a naturally infected sheep and a naturally infected duck. *Proc. Helminthol. Soc. Wash.* 14:28-30.
- _____, and H. Zimmerman. 1945. The biological status of Sarcocystis. *J. Parasitol.* 31(Suppl.):13.
- _____, _____, and D. Jaquette. 1946. Transmission of Sarcocystis to swine. *Proc. Helminthol. Soc. Wash.* 12:1-11.
- Thomas, V., and A.S. Dissanaik. 1978. Antibodies to Sarcocystis in Malaysians. *Trans. R. Soc. Trop. Med. Hyg.* 72:303-306.
- Wallace, G.D. 1973. Sarcocystis in mice inoculated with Toxoplasma-like oocysts from cat feces. *Science* 180:1375-1377.
- Zaman, V., and F.C. Colley. 1975. Light and electron microscopic observations of the life cycle of Sarcocystis orientalis sp. n. in the rat (Rattus norvegicus) and the Malaysian reticulated python (Python reticulatus). *Z. Parasitenkd.* 47:169-185.

APPENDIX

ABBREVIATIONS OF STRUCTURAL FEATURES

A	Amylopectin granule
C	Conoid
CH	Chamber-like hollow in ground substance
CW	Cyst wall
DM	Degenerate merozoite
DR	Ductule of rhoptrie
DS	Degenerate septum
ER	Endoplasmic reticulum
GO	Golgi body
GS	Ground substance
IM	Inner membrane of the pellicle
ME	Merozoite
MF	Microfibril
MFI	Muscle fibril
MI	Mitochondria
MIH	Mitochondria of the host cell
MM	Middle membrane of the pellicle
MP	Micropore
MT	Microtubule
N	Nucleus
OM	Outer membrane of the pellicle
P	Polar Ring
PA	Palisade-like protrusion of the primary cyst wall
PE	Pellicle
PC	Preconoidal ring
PH	Primary cyst wall
PHM	Unit membrane of the primary cyst wall
PN	Perinuclear space
PR	Pore
R	Rhoptrie
RB	Ribosome
S	Septum
SH	Secondary cyst wall
ST	Subpellicular microtubule

STRUCTURAL COMPONENTS TERMINOLOGY

[Arranged in order of occurrence from the exterior to interior of the sarcocyst]

Primary Cyst Wall--The primary cyst wall consists of a unit membrane and an underlying osmiophilic ground substance. The primary cyst wall originates from the parasitophorous vacuole and may develop protrusions characteristic of different species (Mehlhorn et al., 1976).

Secondary Cyst Wall--The secondary cyst wall consists of fibrillar material of the parasitized host cell (Mehlhorn et al., 1976).

Pellicle--The pellicle consists of an outer unit membrane and an inner layer composed of two unit membranes. The outer unit membrane and the inner membranous layer are separated by an osmiophobic space. The outer membrane is continuous and encompasses the entire merozoite. The inner membranous layer terminates at the anterior and posterior polar rings (Scholtyseck, 1973).

Polar Rings--The polar rings are osmiophilic thickenings formed by the inner membranous layer of the pellicle. The polar rings may function as supporting structures around the anterior and posterior openings of the inner layer of the

pellicle. The subpellicular microtubules attach to the anterior polar ring. The anterior polar ring may serve a role in the movement of the conoid (Scholtyseck, 1973).

Subpellicular Microtubules--The subpellicular microtubules are cytoplasmic structures having a structural connection with the inner layer of the pellicle. The close association of the inner layer of the pellicle and the subpellicular microtubules suggest they maybe a single funtional unit, probably related to motility. Twenty-two subpellicular microtubules attached to the anterior polar ring extend posteriorly as far as the nucleus (Scholtyseck, 1973; Mehlhorn and Heydorn, 1978).

Conoid--The conoid consists of a truncated hollow cone of twenty spirally arranged fibrillar structures surmounted by two preconoidal rings. The conoid is an organelle which can be protruded and retracted to function in the penetration of host cells. The anterior polar ring which surrounds the conoid maintains the shape of the merozoite's anterior pole (Scholtyseck, 1973; Mehlhorn and Heydorn, 1978).

Rhoptries--(paired organelles) Rhoptries are club-shaped, drop-shaped, elongate, or tortuous in shape. Ductules extend anteriorly from the rhoptries to the conoid. The gland-like

appearance of the rhoptries suggests that they may secrete a proteolytic enzyme to assist the conoid in penetrating host cells. (Scholtyseck, 1973).

Micronemes--(sarconemes, toxonemes) Micronemes are small osmiophilic convoluted tubules, typically distributed in the anterior third or along the margin of the merozoite. These structures appear as "rice grains" because the tortuous convolutions preclude longitudinal sectioning. Micronemes may function in conjunction with the rhoptries to establish a single secretory functional unit (Scholtyseck, 1973; Mehlhorn and Heydorn, 1978).

Micropores--(micropyle) Micropores are punctate invaginations of the outer unit membrane and the inner membranous layer. The outer unit membrane remains continuous while the inner membranous layer forms a cylindrical structure. The inner membranous layer surrounds the invaginated outer unit membrane. A cross section through the micropore displays two concentric osmiophilic rings, the inner ring representing the unit membrane and the outer ring representing the cylindrical inner membranous layer. The micropore functions in the acquisition of nutrients through pinocytosis and phagocytosis. Cytoplasmic vacuoles arise from the marginal constriction of the micropore's opening (Scholtyseck, 1973).

LIFE CYCLE NOMENCLATURE

[Arranged in life cycle order]

Meront--(trophozoite, merozoite) A meront is the motile stage of the ingested parasite, originating from the ingested sporozoite. This motile stage is prevalent during the merogonous or extraintestinal stage of schizogony.

Metrocyte--(schizont, agamont, segmenter) A metrocyte is an encysted meront which undergoes multiple fission divisions during schizogony.

Merozoites--(schizozoite, bradyzoite) A merozoite is a daughter cell of the multiple fission divisions of the metrocyte, generally considered the final and infectious product of the schizogonous stage of the life cycle.

Gamonts--A collective term used to describe the microgametocyte and macrogametocyte.

Microgamete--A microgamete is a small gamete produced by the microgametocyte during the gametogonous stage of the life cycle.

Macrogamete--A macrogamete is a large gamete produced by the macrogametocyte during the gametogonous stage of the life cycle. The fusion of the macrogamete and the microgamete yields a zygote.

Sporocysts--A sporocyst is an intermediate product of zygote sporulation (sporogony) and is the immediate precursor to sporozoites.

Sporozoite--A sporozoite is the daughter cell of the multiple fission division of the zygote, generally considered a final and infective product of the gametogonous stage of the life cycle.

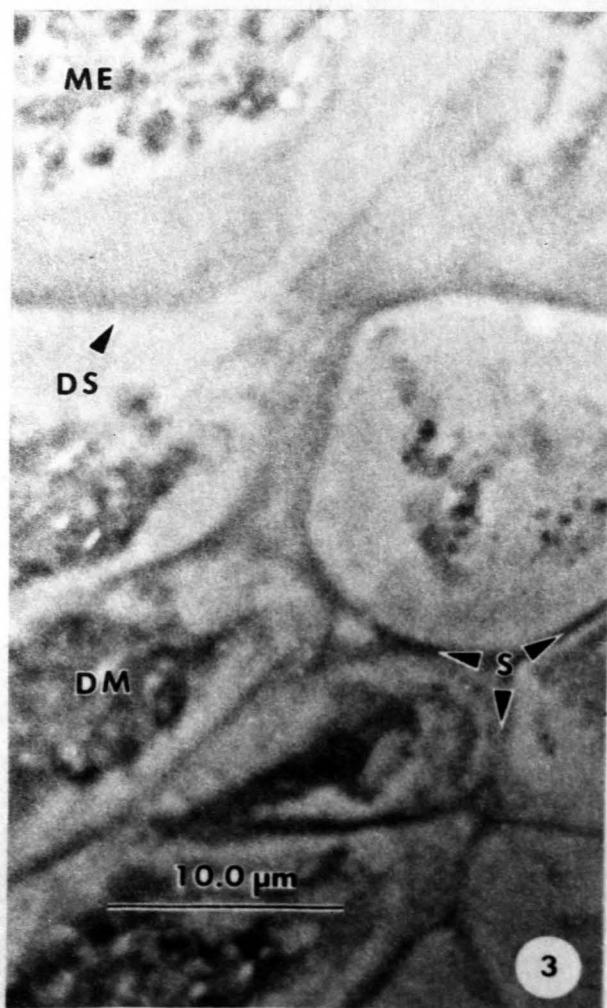
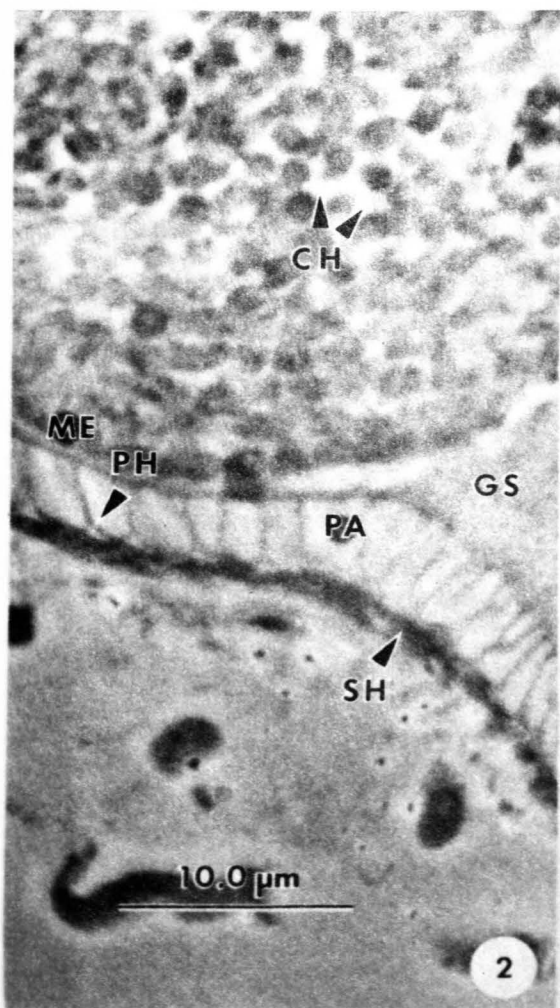
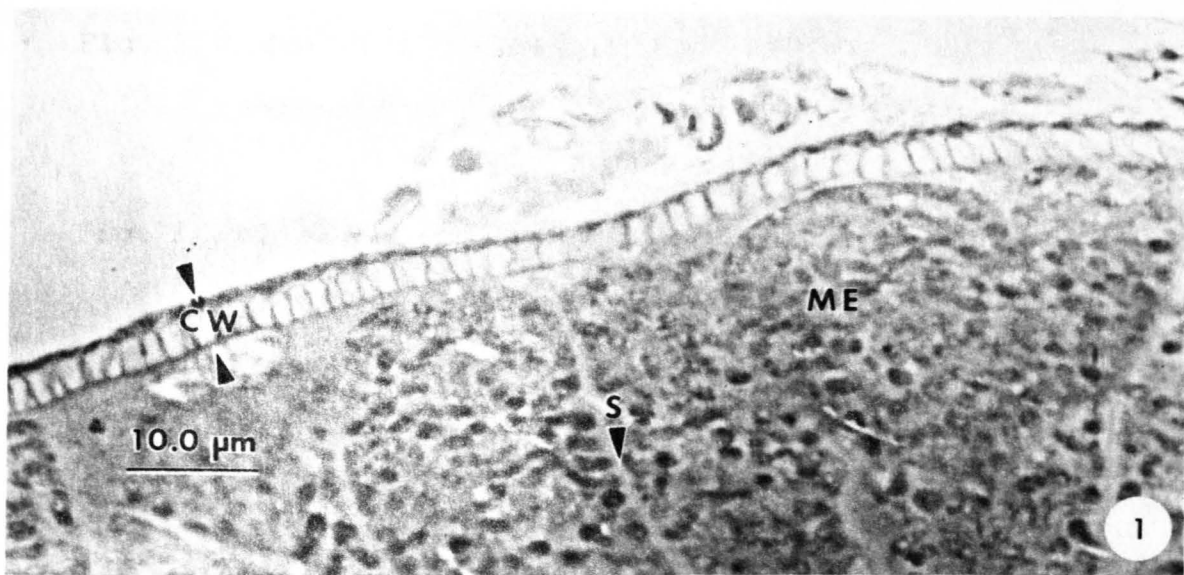

Fig. 1 Radially striated cyst wall of the
sarcocyst (Phase microscopy) [1,500X]

Fig. 2 Palisade-like protrusions of the primary
cyst wall (Phase microscopy) [2,750X]

Fig. 3 Degenerate compartments in central regions
of the sarcocyst (Phase microscopy) [2,750X]

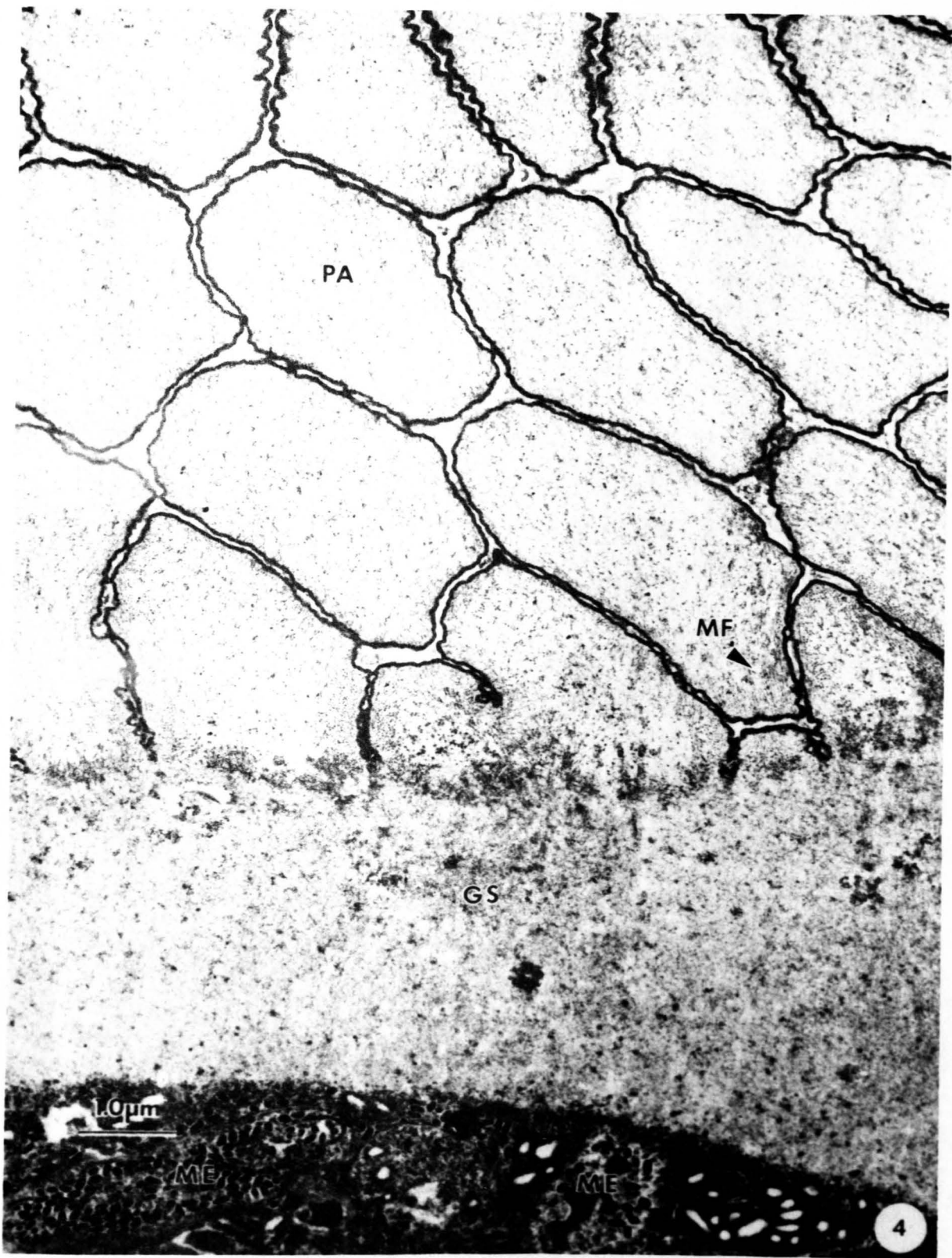


Fig. 4 Primary cyst wall displaying overlapping villi
and a thick underlying ground substance [14,000X]



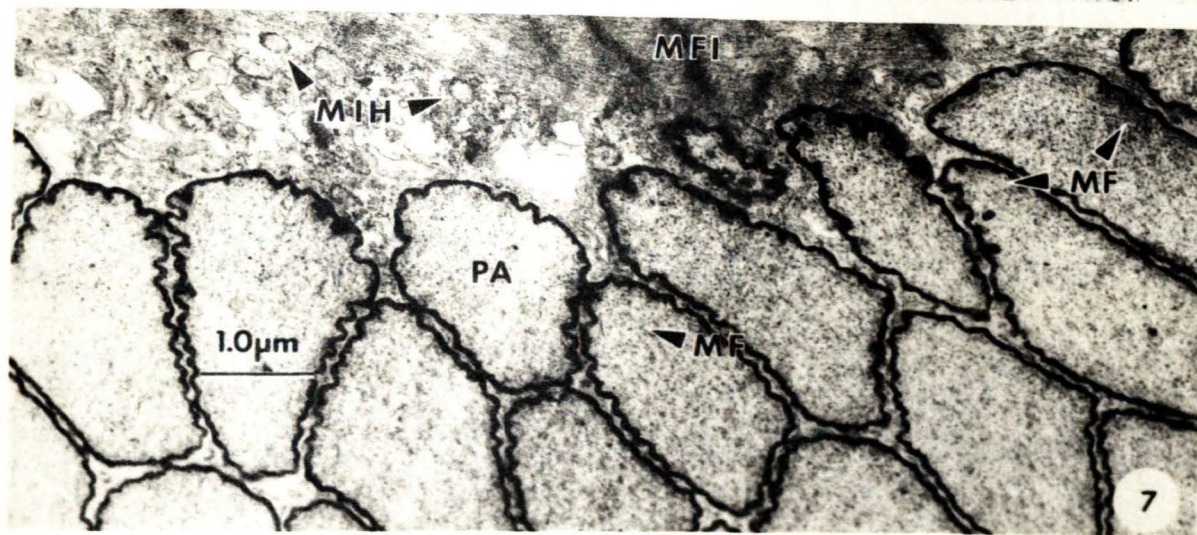
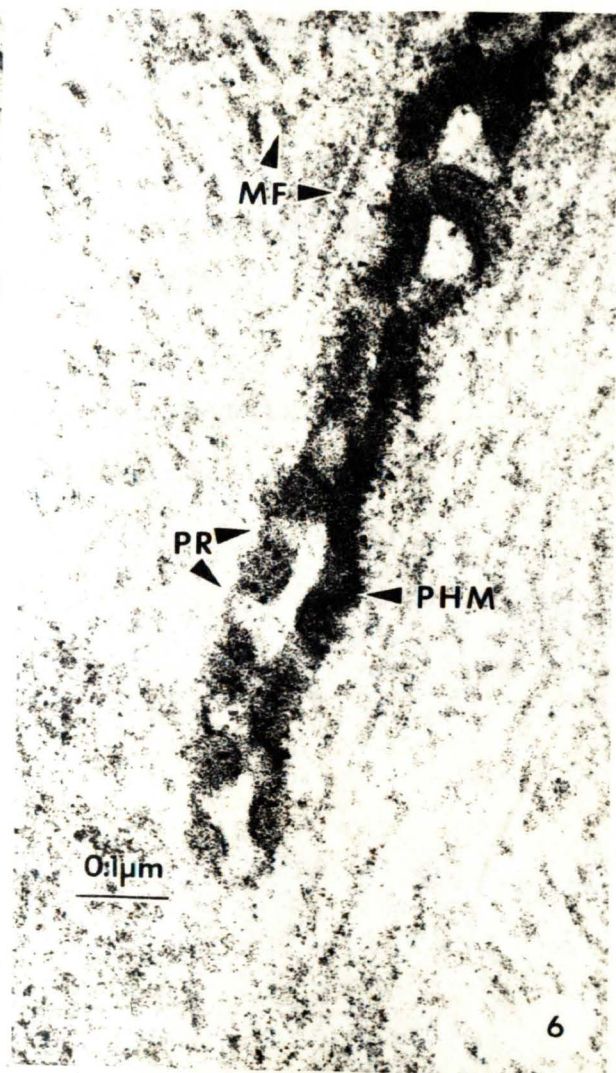
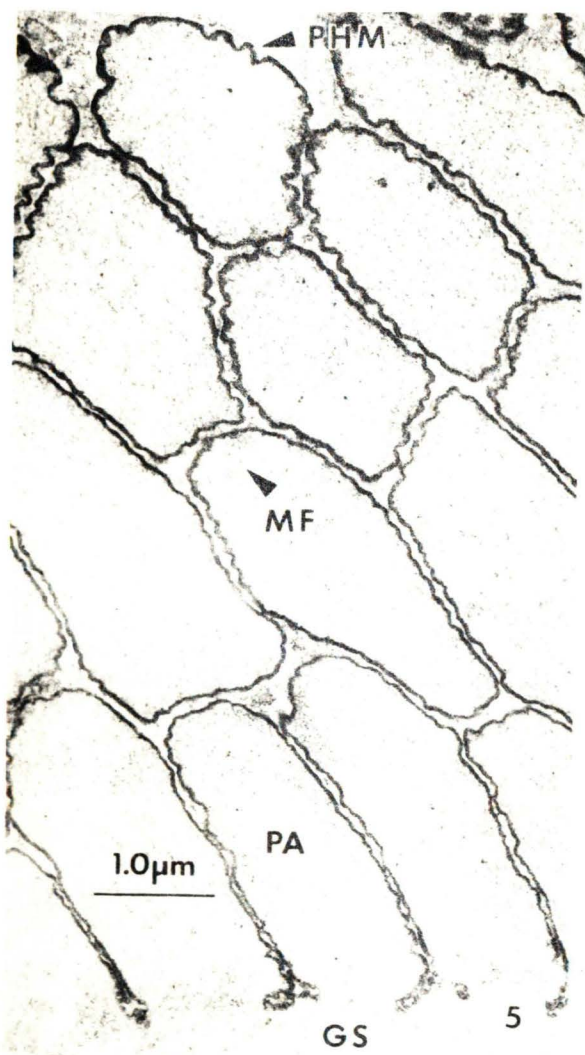


Fig. 5 Palisade-like protrusions and overlying
secondary cyst wall [13,800X]

Fig. 6 Invaginations in the unit membrane displaying
pore-like structures [105,000X]

Fig. 7 Palisade-like protrusions displaying
peripherally located microfibrils and
overlying secondary cyst wall [12,600X]

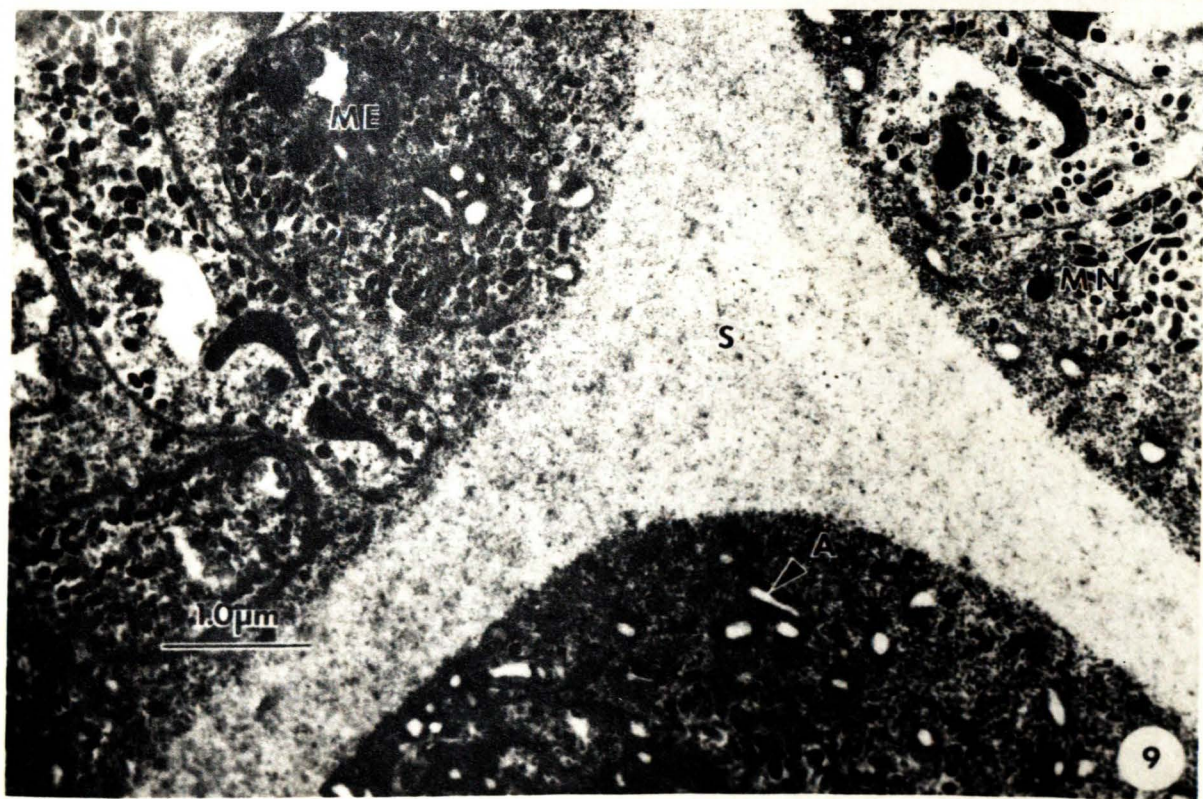
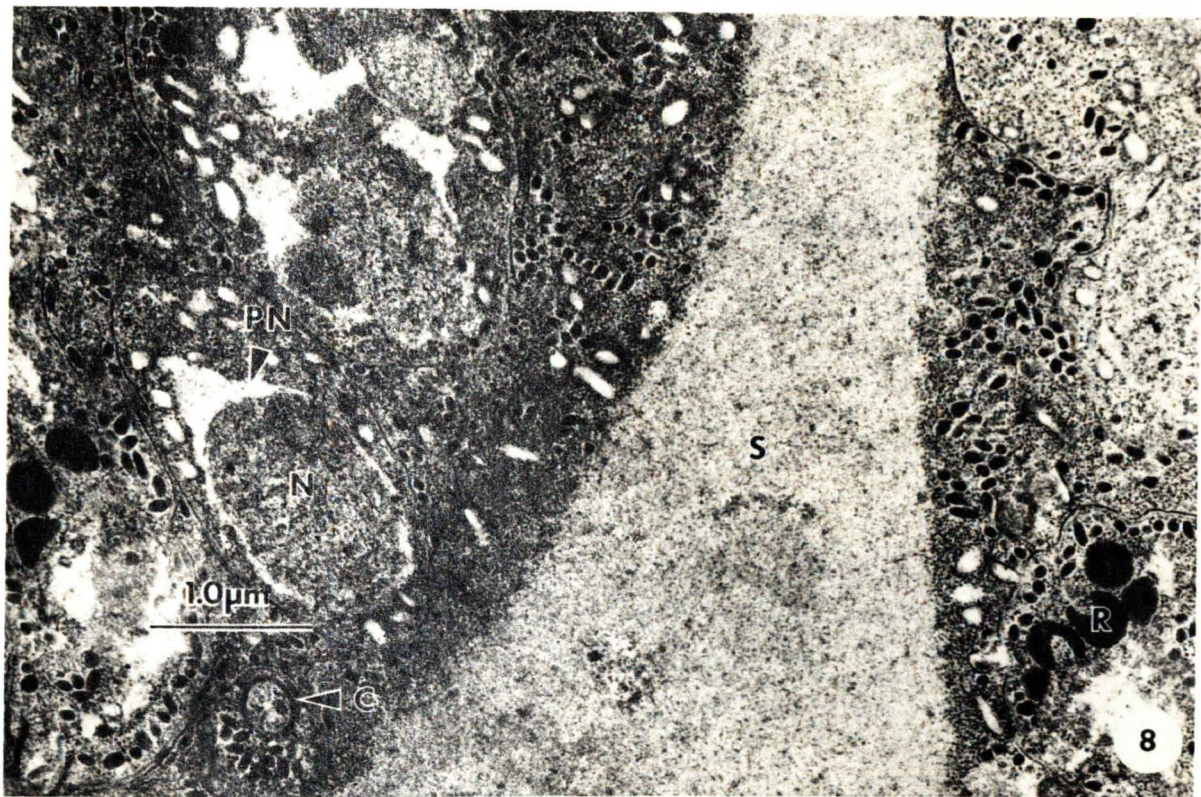


Fig. 8 A septum separating two merozoite-filled compartments [18,200X]

Fig. 9 A triangular column formed by the anastomosis of septa [17,000X]



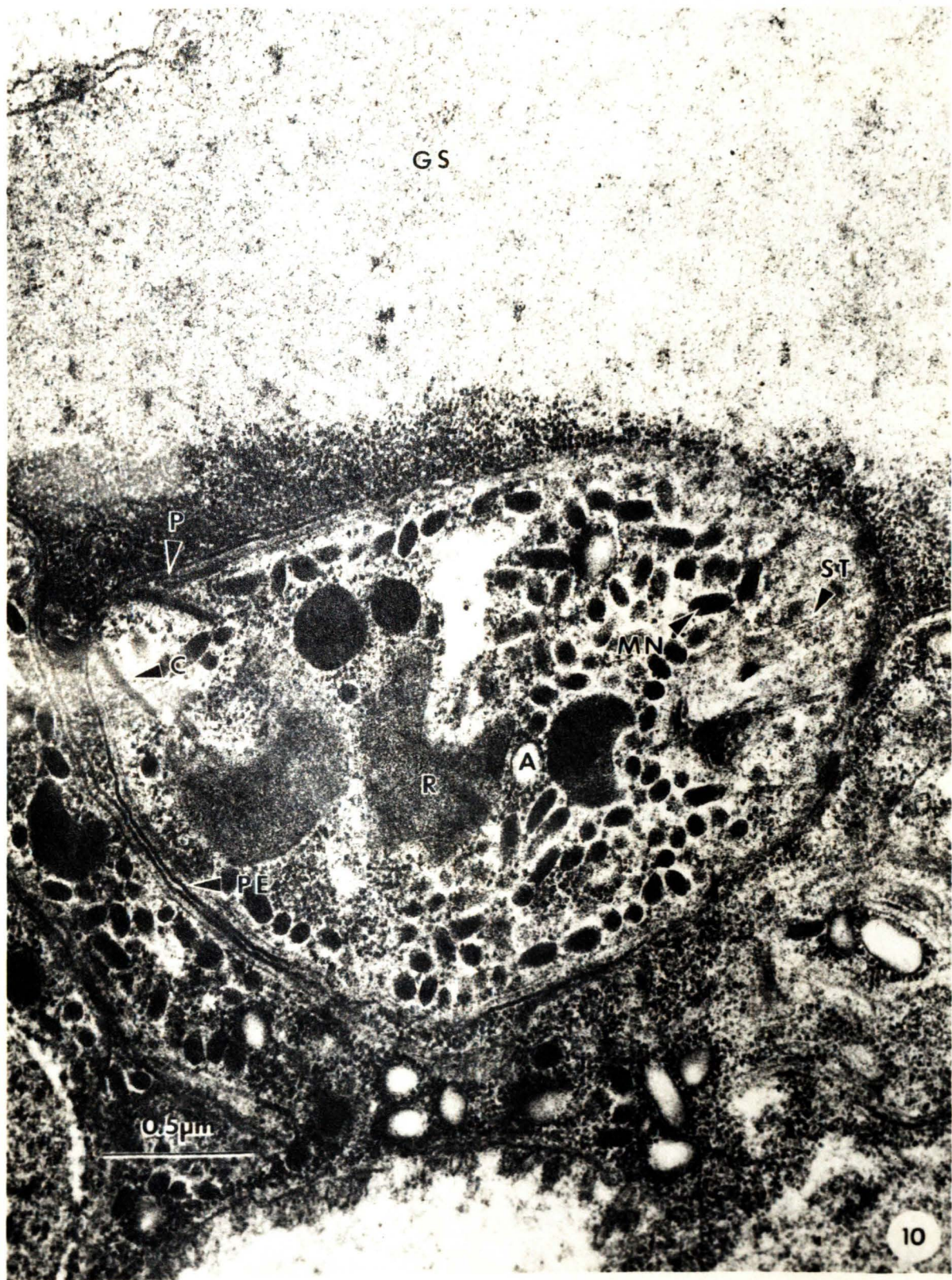


Fig. 10 Merozoite suspended in the granular intra-
compartmental matrix [41,200X]



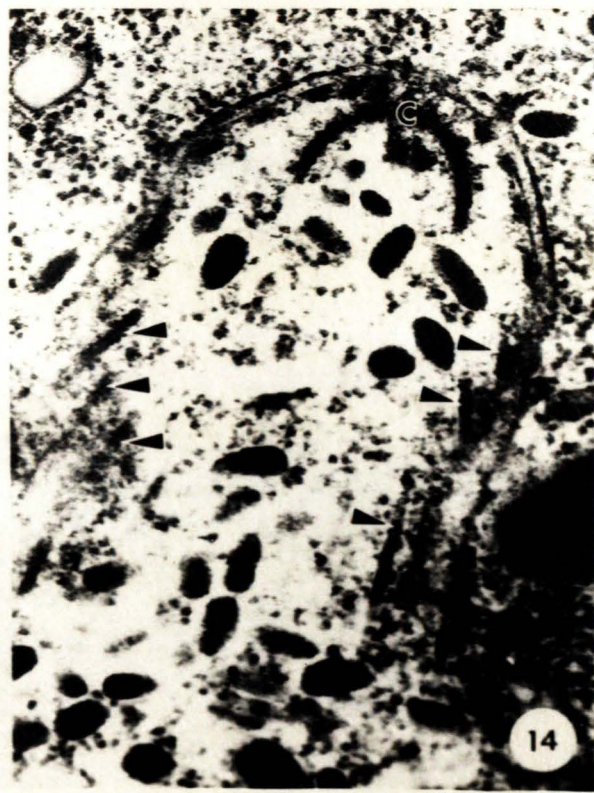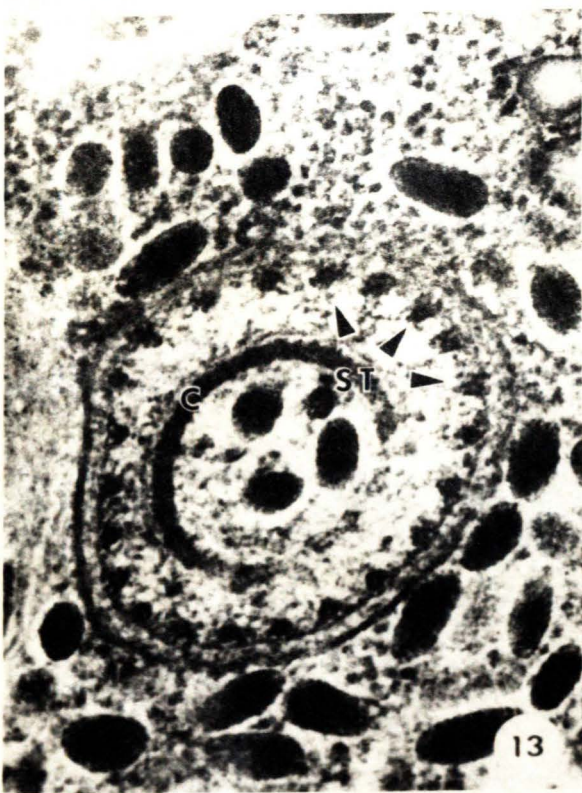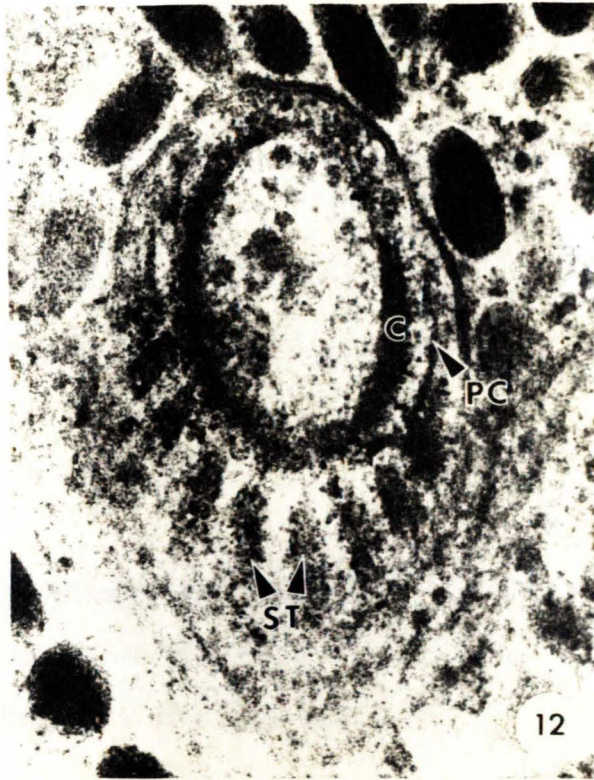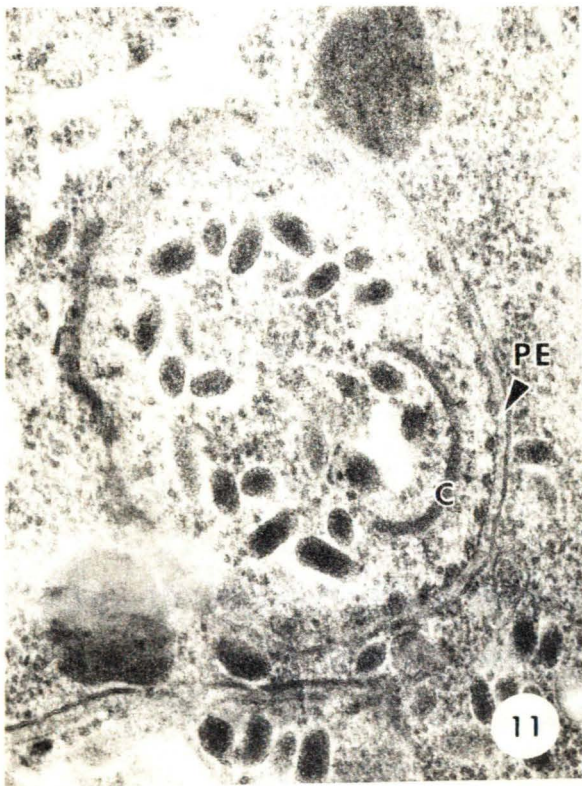


Fig. 11 An oblique section through the apical complex displaying the juxtaposition of the pellicle and subpellicular microtubules [52,700X]

Fig. 12 An oblique section through the apical complex displaying subpellicular microtubules and a preconoidal ring [97,800X]

Fig. 13 Transverse section of the apical complex displaying juxtaposition of the subpellicular microtubules and the pellicle [74,100X]

Fig. 14 Longitudinal section through a merozoite displaying subpellicular microtubules (arrows) [50,900X]

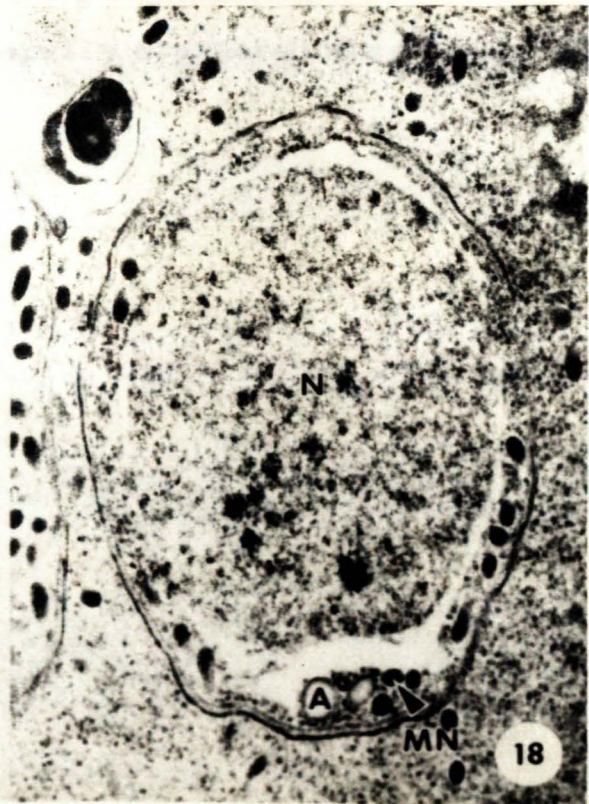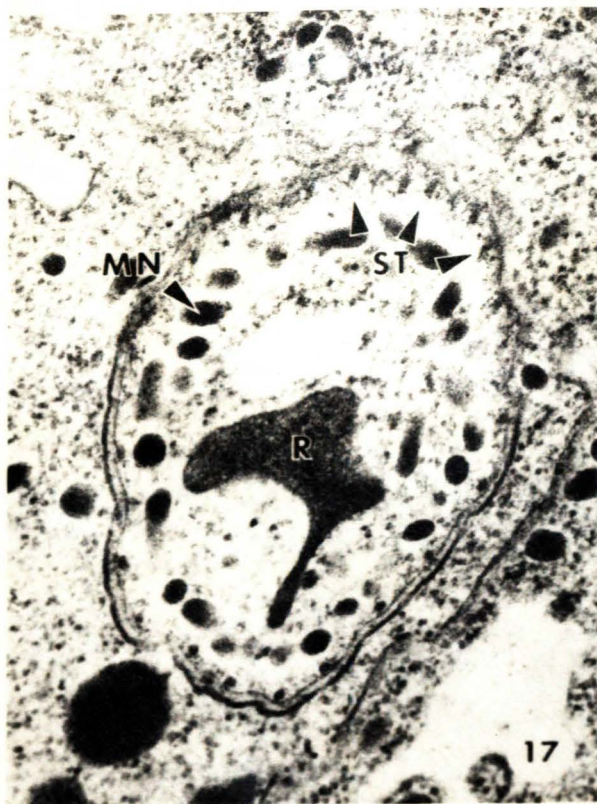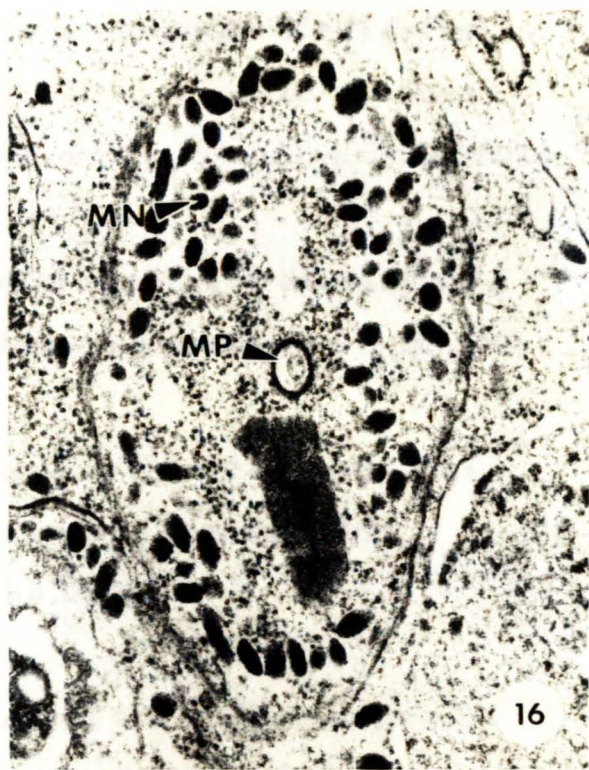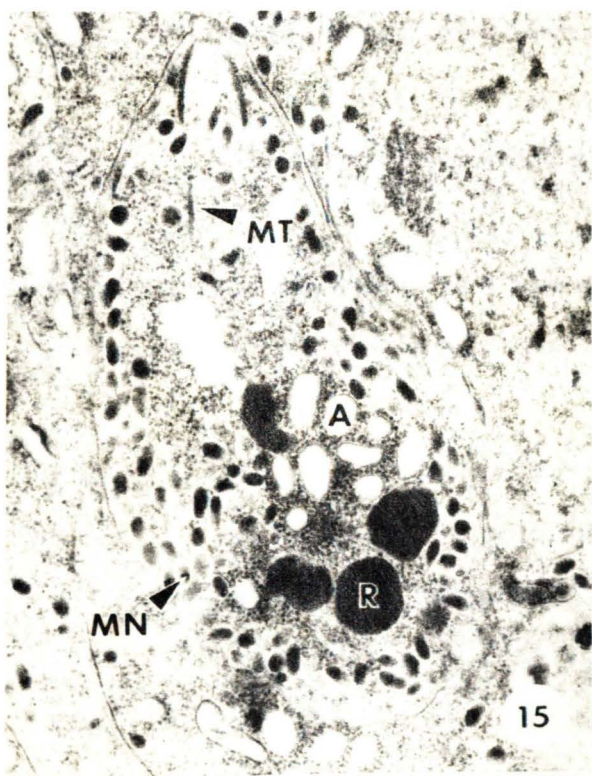
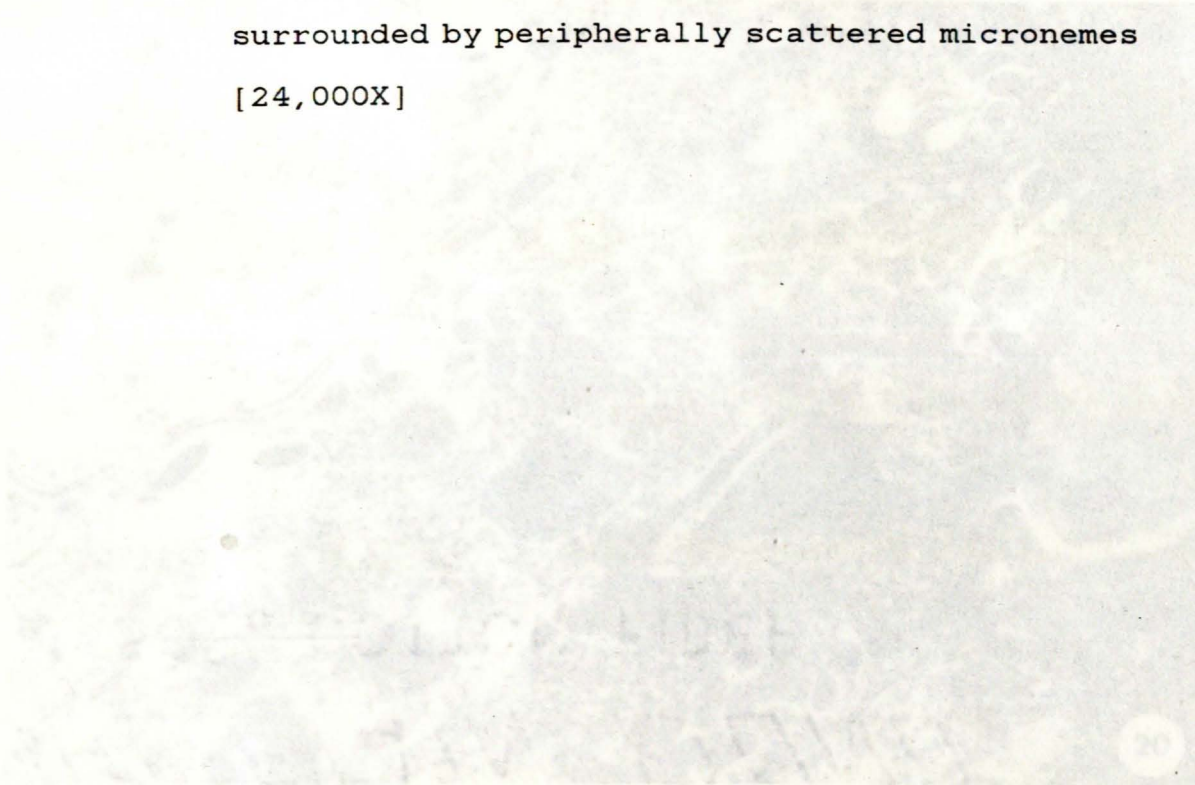


Fig. 15 Oblique section through a merozoite displaying peripherally concentrated micronemes and free-ribosome embossed amylopectin granules [28,100X]

Fig. 16 Oblique section through a merozoite displaying a transverse section through a micropore [68,300X]

Fig. 17 Oblique section through a merozoite displaying peripherally concentrated micronemes and a lobular rhoptrie [34,000X]

Fig. 18 Transverse section through the posterior region of a merozoite displaying the nucleus surrounded by peripherally scattered micronemes [24,000X]



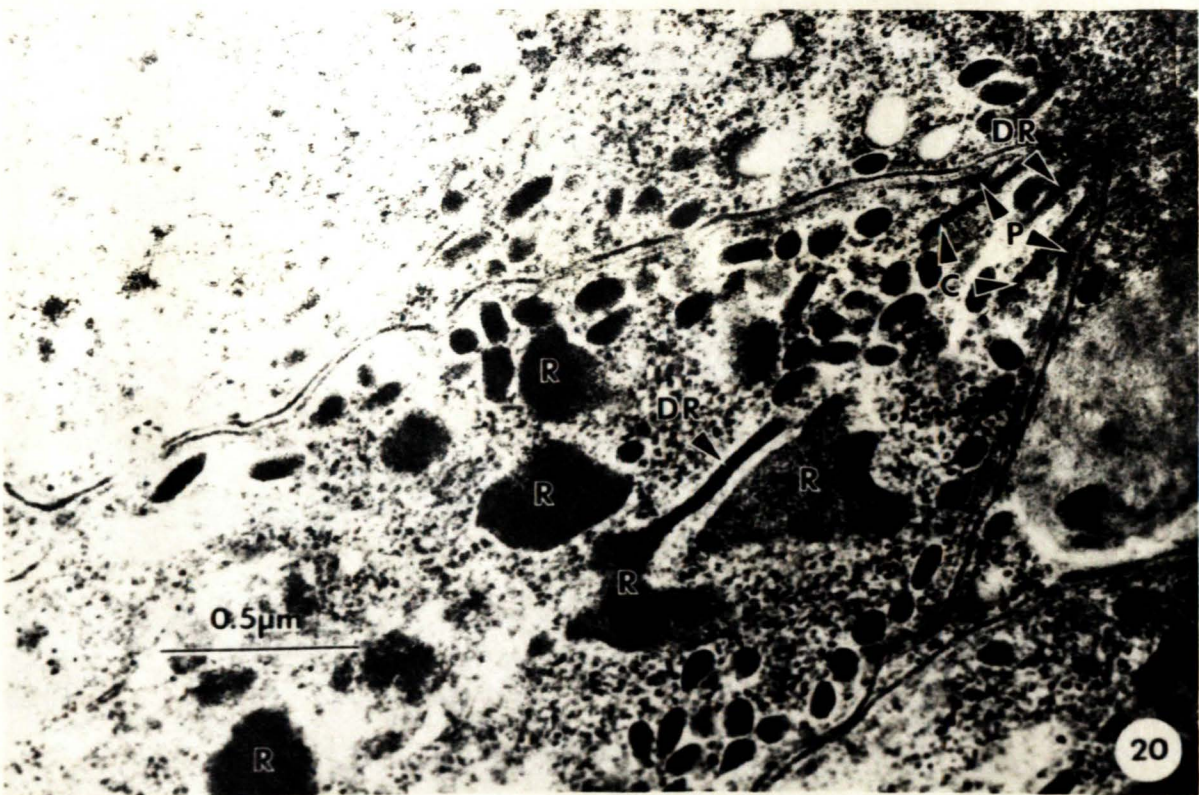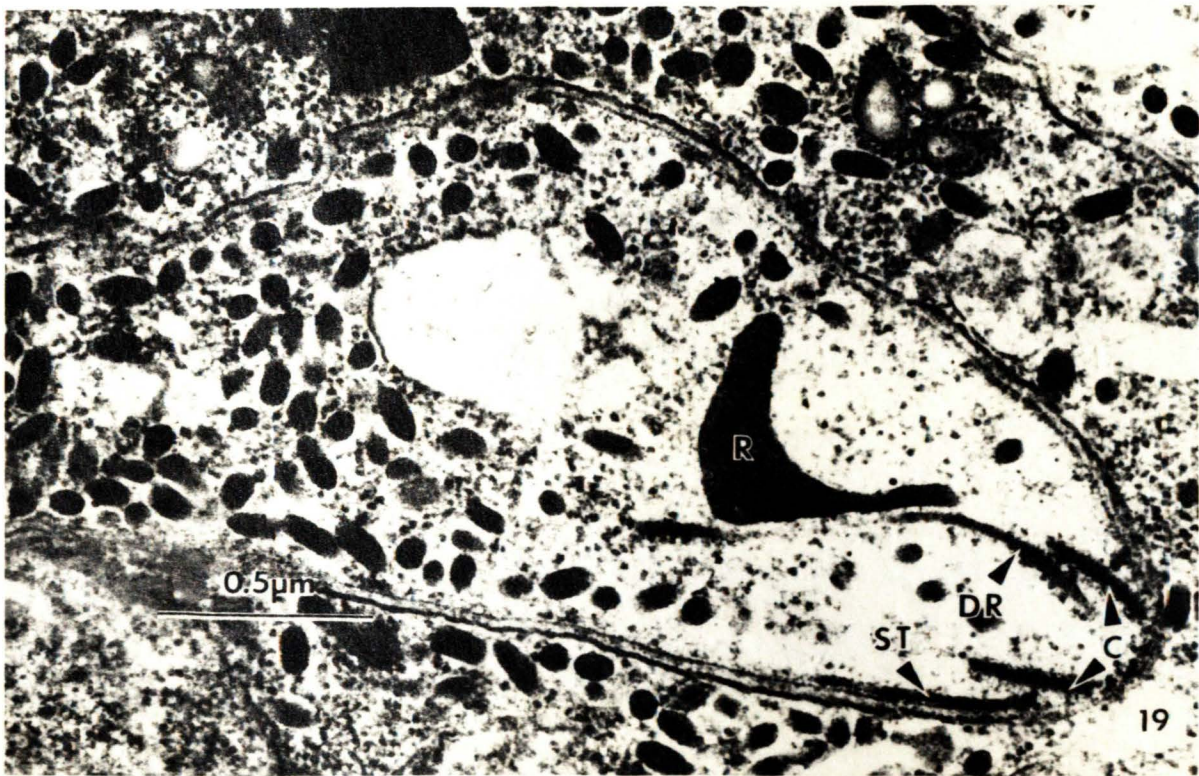


Fig. 19 The apical complex of the merozoite [48,800X]

Fig. 20 The apical complex of a merozoite displaying
the anterior polar ring [45,000X]



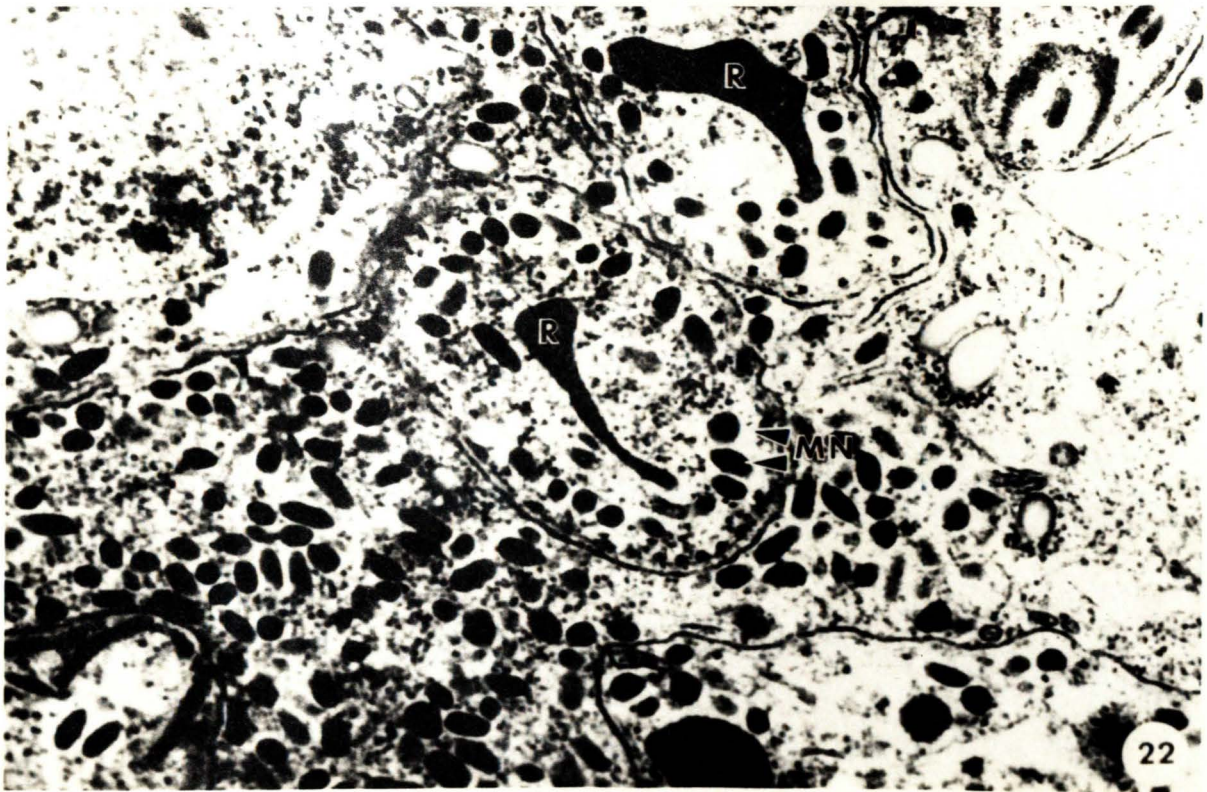
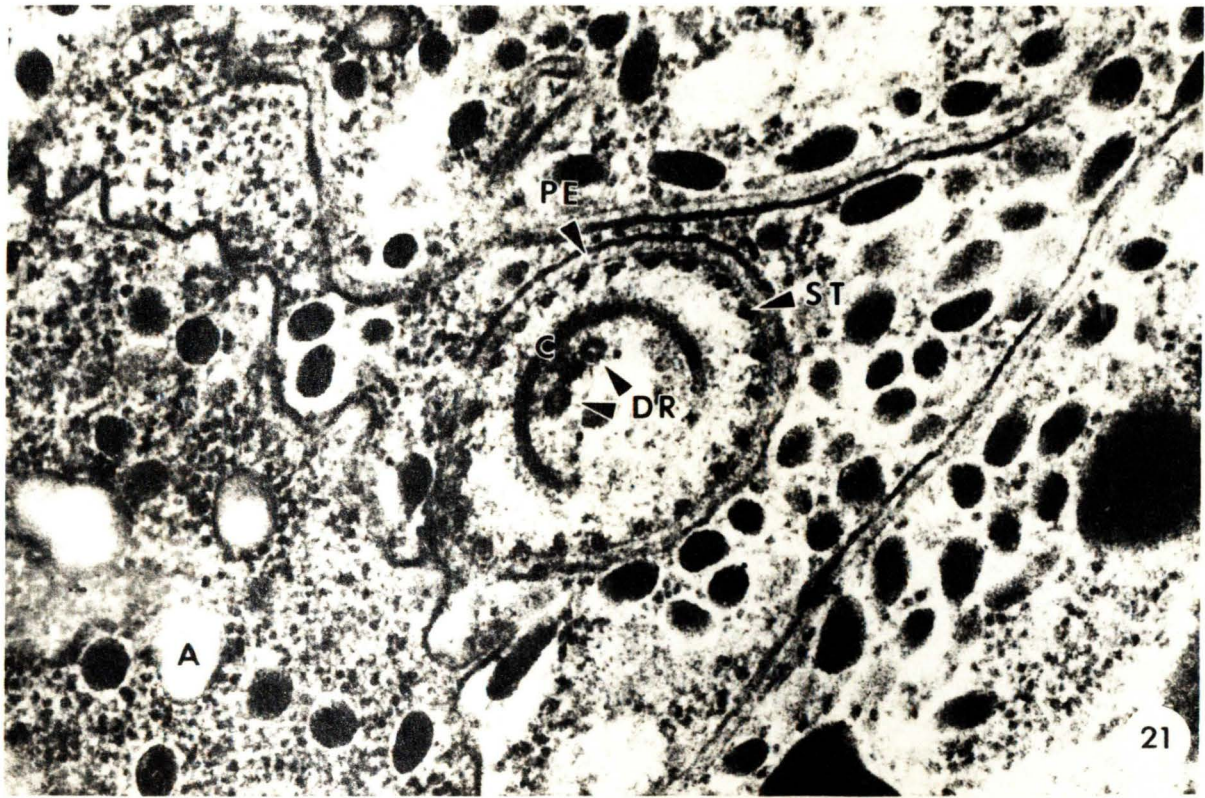


Fig. 21 Transverse section through the apical complex displaying transverse sections of rhoptries ductules [57,800X]

Fig. 22 Peripherally scattered micronemes in an oblique section of a merozoite [34,700X]

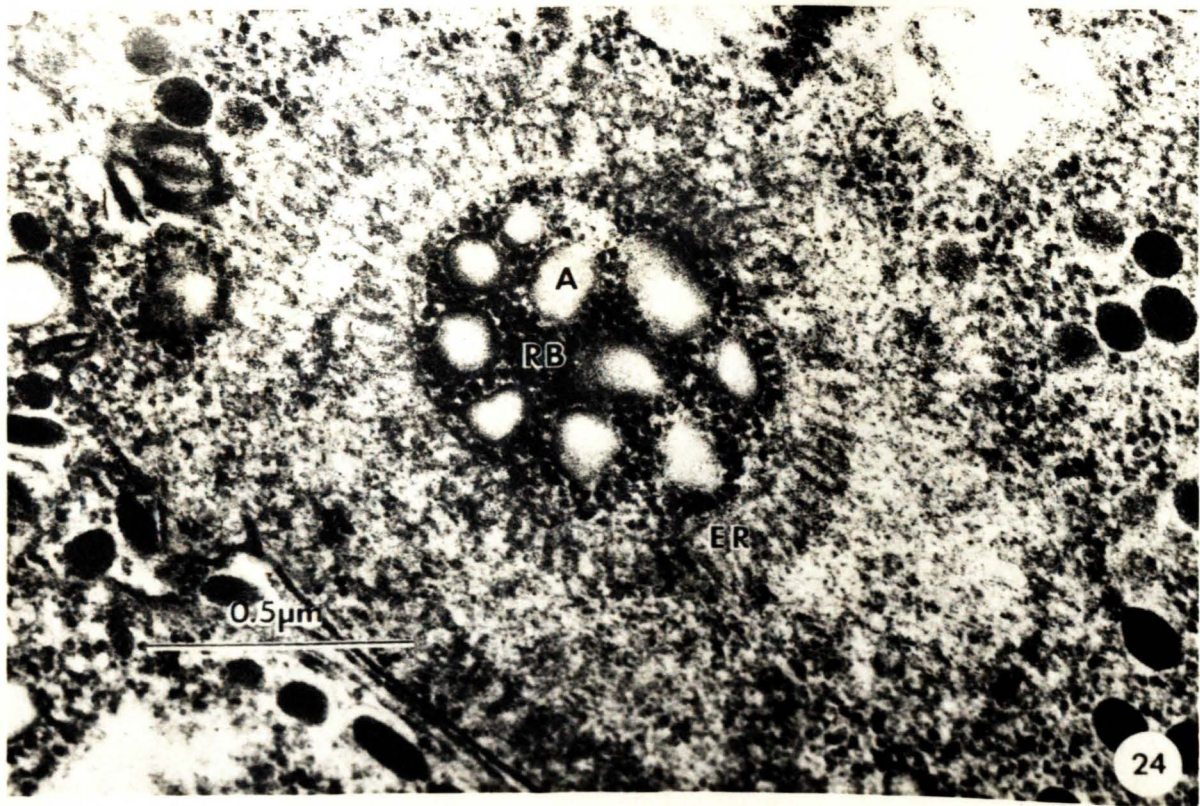
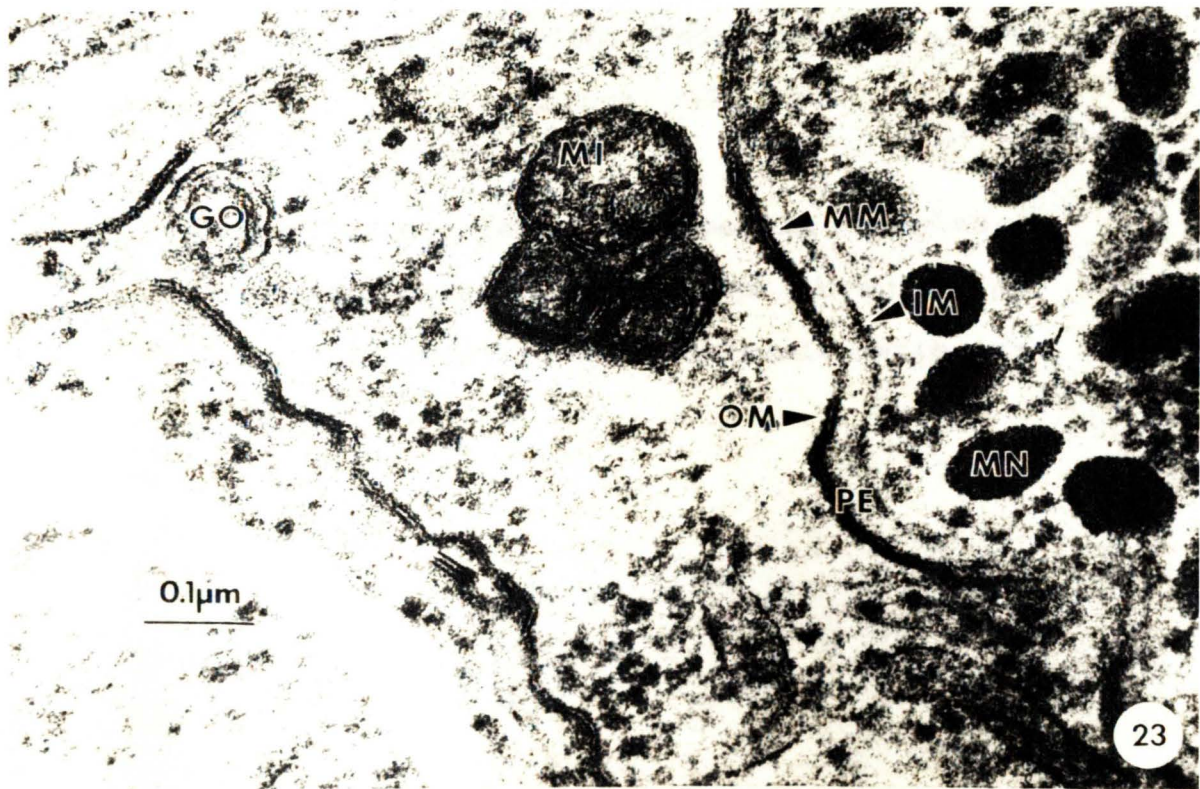
Fig. 23 Mitochondria and golgi bodies not contained
within a unit membrane [122,000X]

Fig. 24 Spherical cluster of amylopectin granules
embossed with free-ribosomes surrounded by
concentric layers of endoplasmic reticulum
[60,000X]



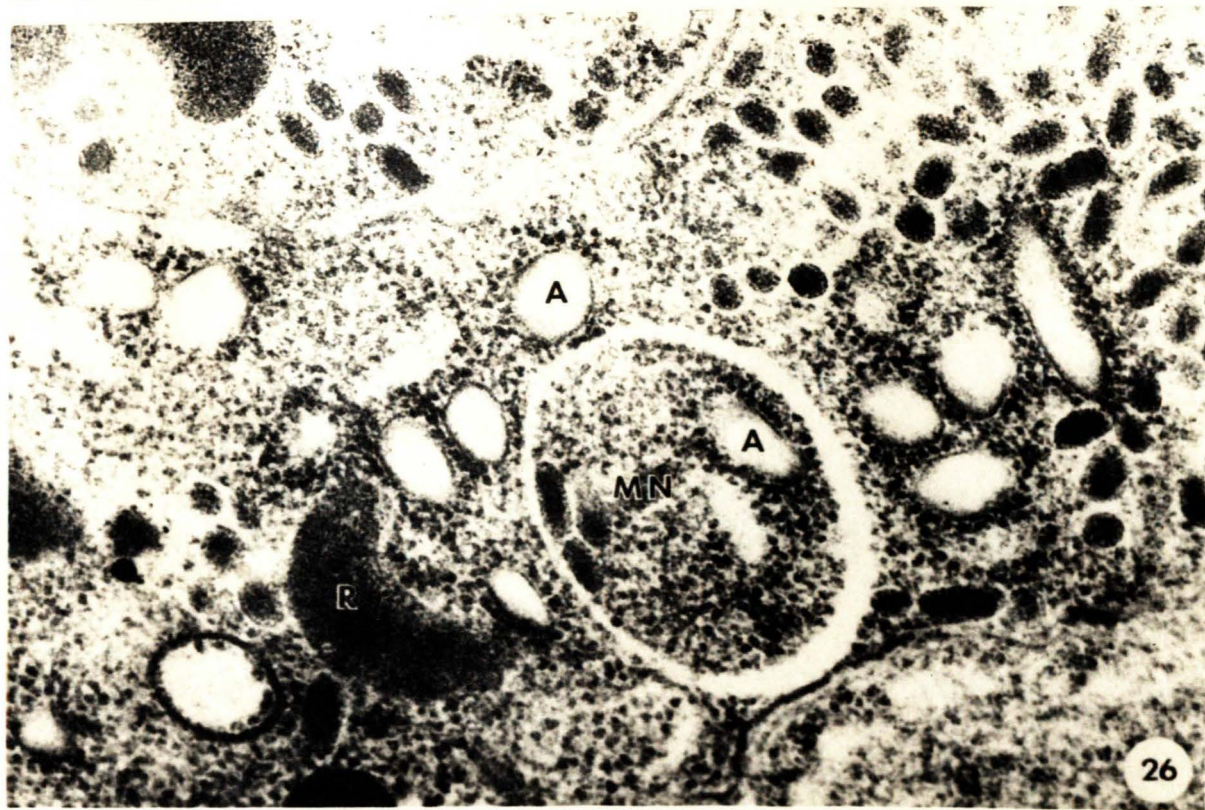
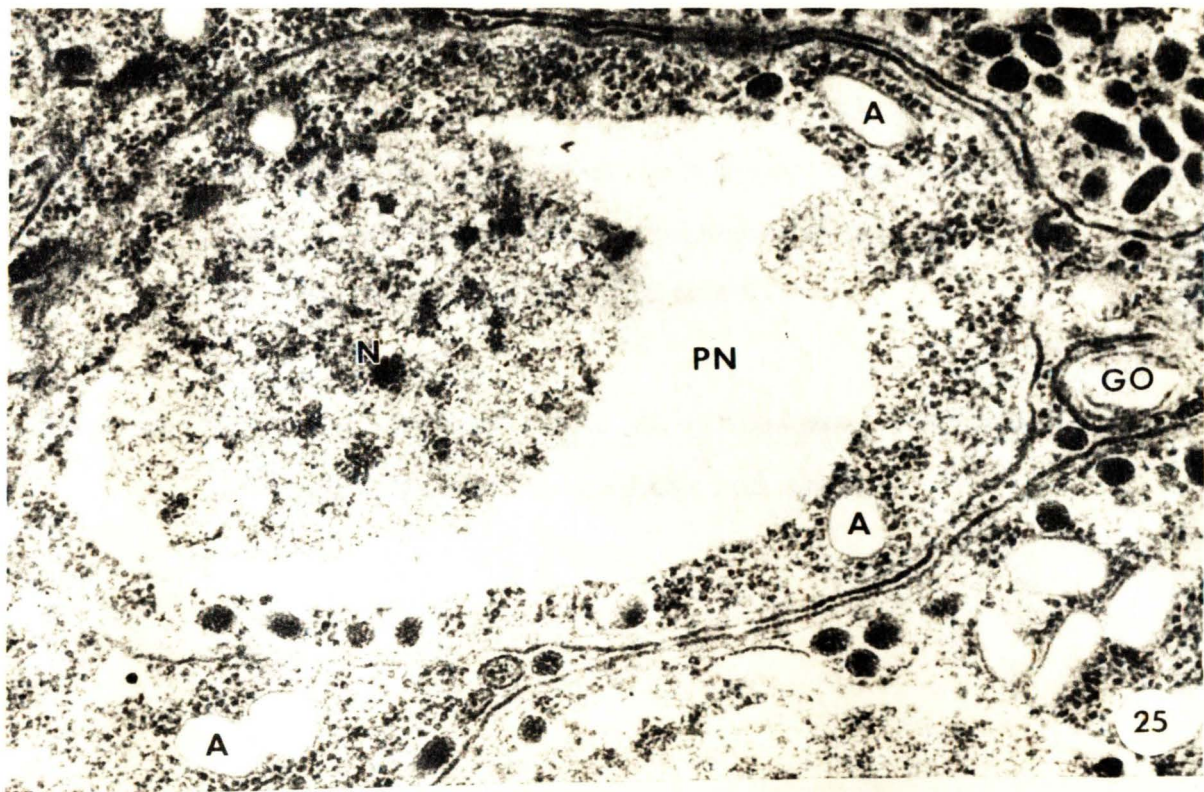


Fig. 25 Peripherally scattered micronemes and amylopectin granules in an oblique section through the posterior region of a merozoite (note the deteriorated cytoplasm in the perinuclear space) [52,000X]

Fig. 26 Vacuolar condensation of cytoplasm, micronemes and amylopectin granules [65,200X]

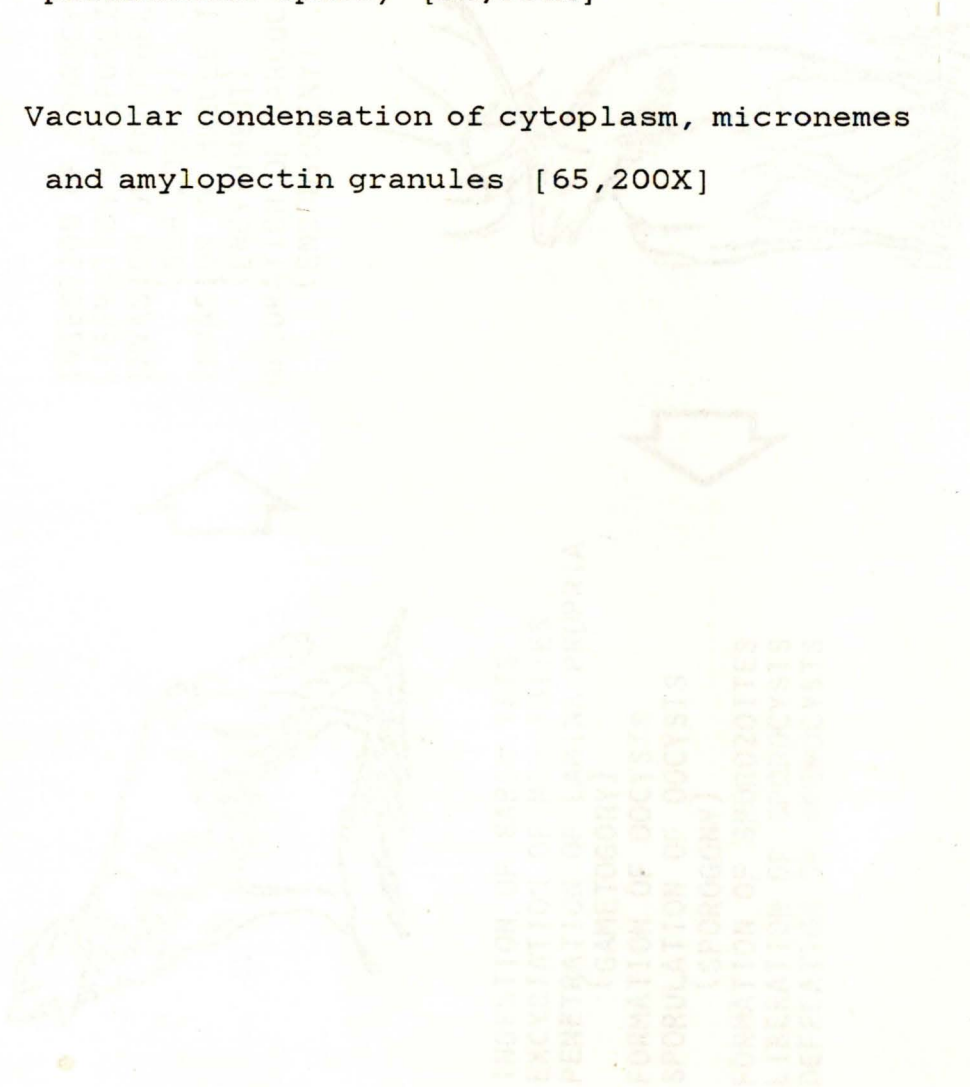
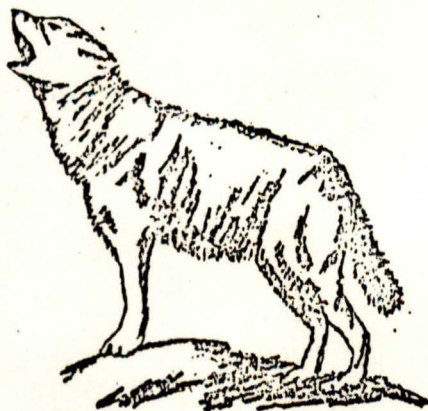

FIG. 27 PROPOSED LIFE CYCLE OF THE PARASITE IN THE HUMAN HOST



INGESTION OF SPORO CYSTS
LIBERATION OF SPOROZOITES
INVASION OF ENDOTHELIAL TISSUES
(SCHIZOGONY)
INVASION OF MUSCLE TISSUE
(ENCYSTMENT)
MATURATION OF SARCO CYSTS
(ENDODYOGENY)

INGESTION OF SARCO CYSTS
EXCYSTATION OF MEROZOITES
PENETRATION OF LAMINA PROPRIA
(GAMETOGONY)
FORMATION OF OOCYSTS
SPORULATION OF OOCYSTS
(SPORO GONY)
FORMATION OF SPOROZOITES
LIBERATION OF SPORO CYSTS
DEFECATION OF SPORO CYSTS



FIG. 27 PROPOSED LIFE CYCLE OF SARCOCYSTIS IN WAPITI AND COYOTE